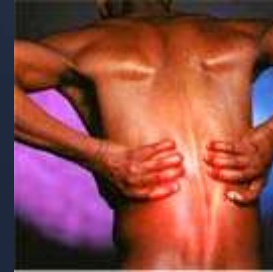

MINIMAL INVASIVE TRANSPSOAS APPROACH FOR COMPLEX SPINAL SURGERY

WAYNE CHENG, MD

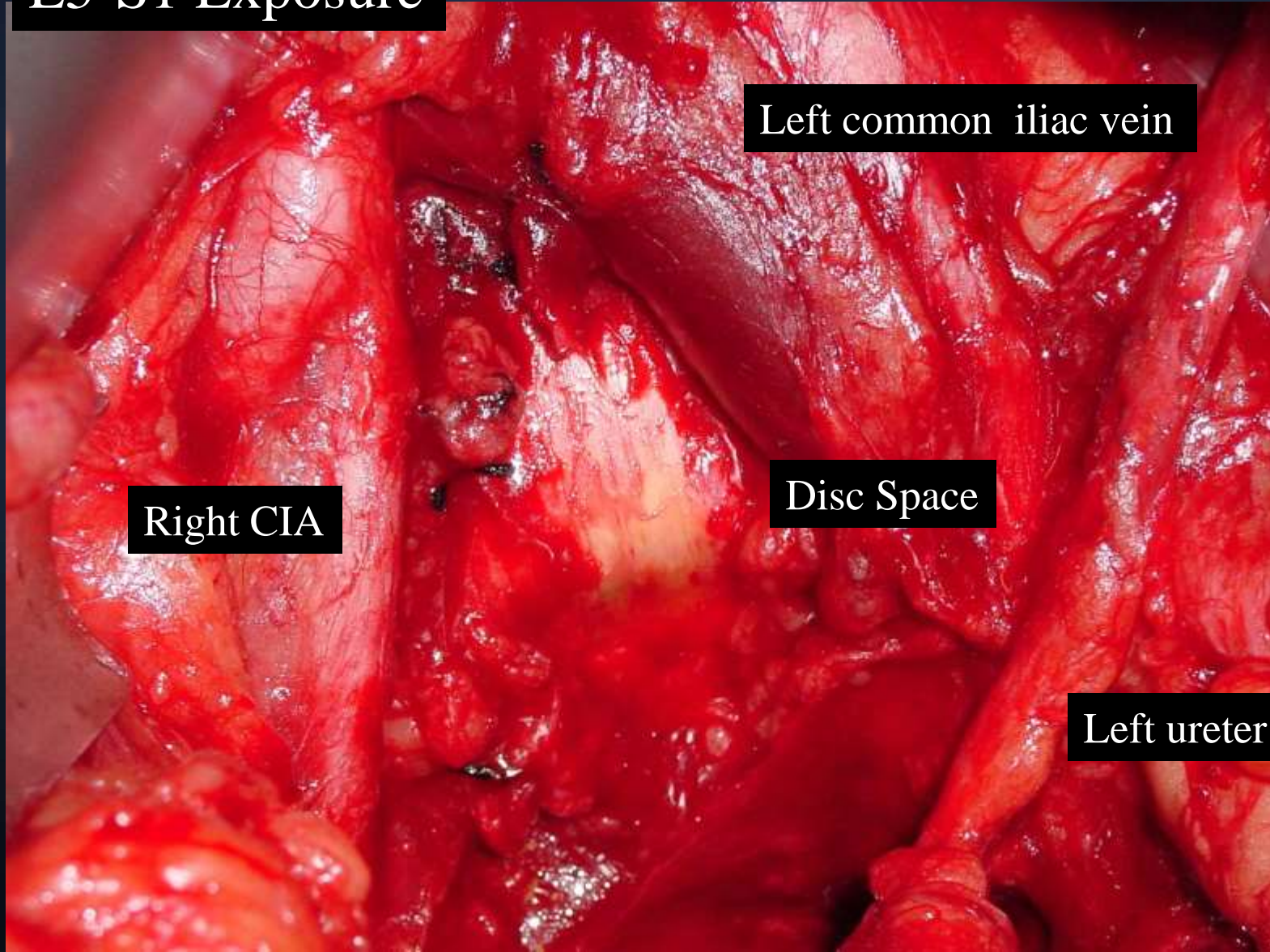
Bones and Spine

POSTERIOR APPROACH - FUSION DISEASE?



ANTERIOR APPROACH

L5-S1 Exposure



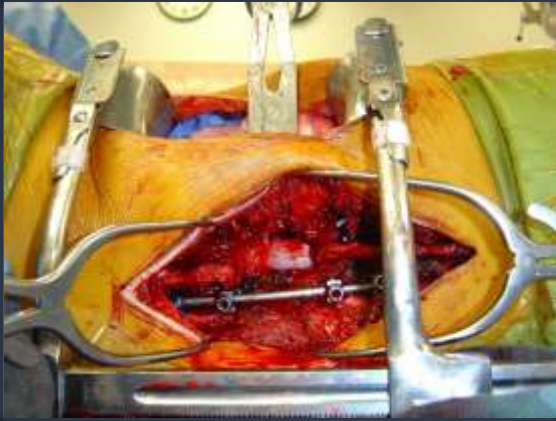
Right CIA

Left common iliac vein

Disc Space

Left ureter

ANTERIOR & POSTERIOR APPROACH



LATERAL TRANSPSOAS-APPROACH LUMBAR PLEXUS

QuickTime™ and a
decompressor
are needed to see this picture.

LUMBAR PLEXUS



Quick
dec
are needed to

QuickTime™ and a
decompressor
are needed to see this picture.

QuickTime™ and a
decompressor
are needed to see this picture.

MIN. INVASIVE + EMG NAV.

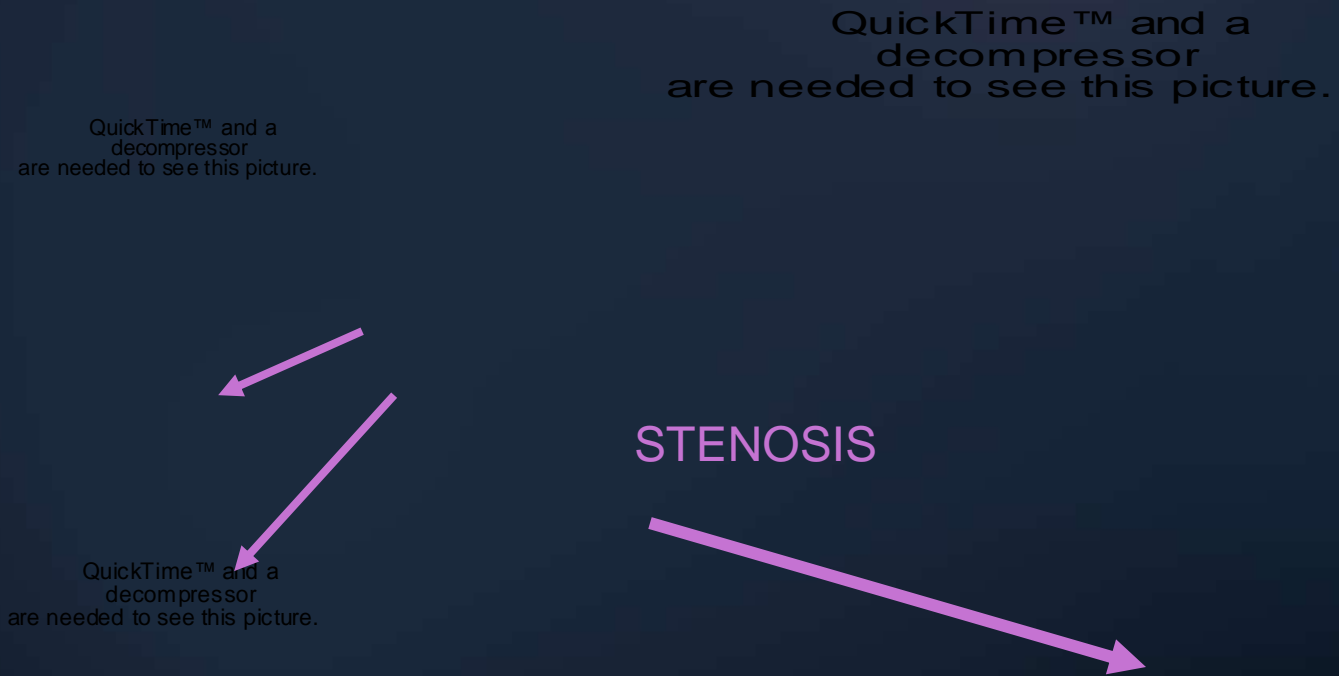


QuickTime™ and a
decompressor
are needed to see this picture.

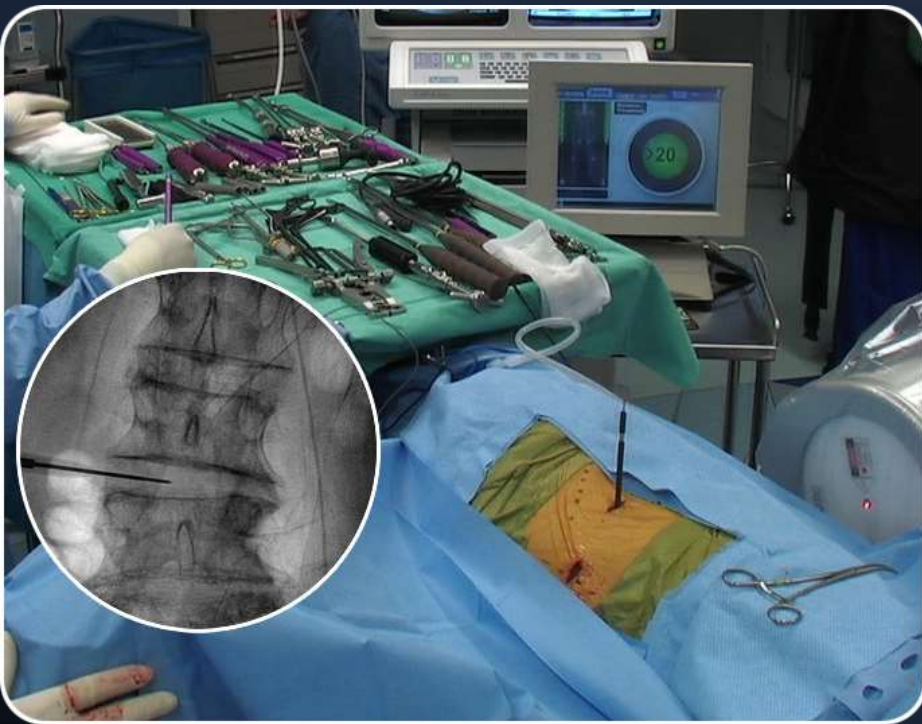
QuickTime™ and a
decompressor
are needed to see this picture.

CASE 1: 46 YO FEMALE, JEHOVAH WITNESS,
NEUROGENIC CLAUDICATION, H/O INFX REQUIRED
MULTIPLE I&D


CASE 1: 46 YO FEMALE, JEHOVAH WITNESS, NEUROGENIC CLAUDICATION, H/O INFX REQUIRED MULTIPLE I&D - *PRE OP MRI*



CASE 1: 46 YO FEMALE, JEHOVAH WITNESS,
NEUROGENIC CLAUDICATION, H/O INFX REQUIRED
MULTIPLE I&D - *INTRA-OP DISC PREPARATION*



CASE 1: 46 YO FEMALE, JEHOVAH WITNESS,
NEUROGENIC CLAUDICATION, H/O INFX REQUIRED
MULTIPLE I&D - **ANTERIOR INTERBODY FUSION**



CASE 1: 46 YO FEMALE, JEHOVAH WITNESS,
NEUROGENIC CLAUDICATION, H/O INFX REQUIRED
MULTIPLE I&D - **ANTERIOR INSTRUMENTATION**

QuickTime™ and a
decompressor
are needed to see this picture.

QuickTime™ and a
decompressor
are needed to see this picture.

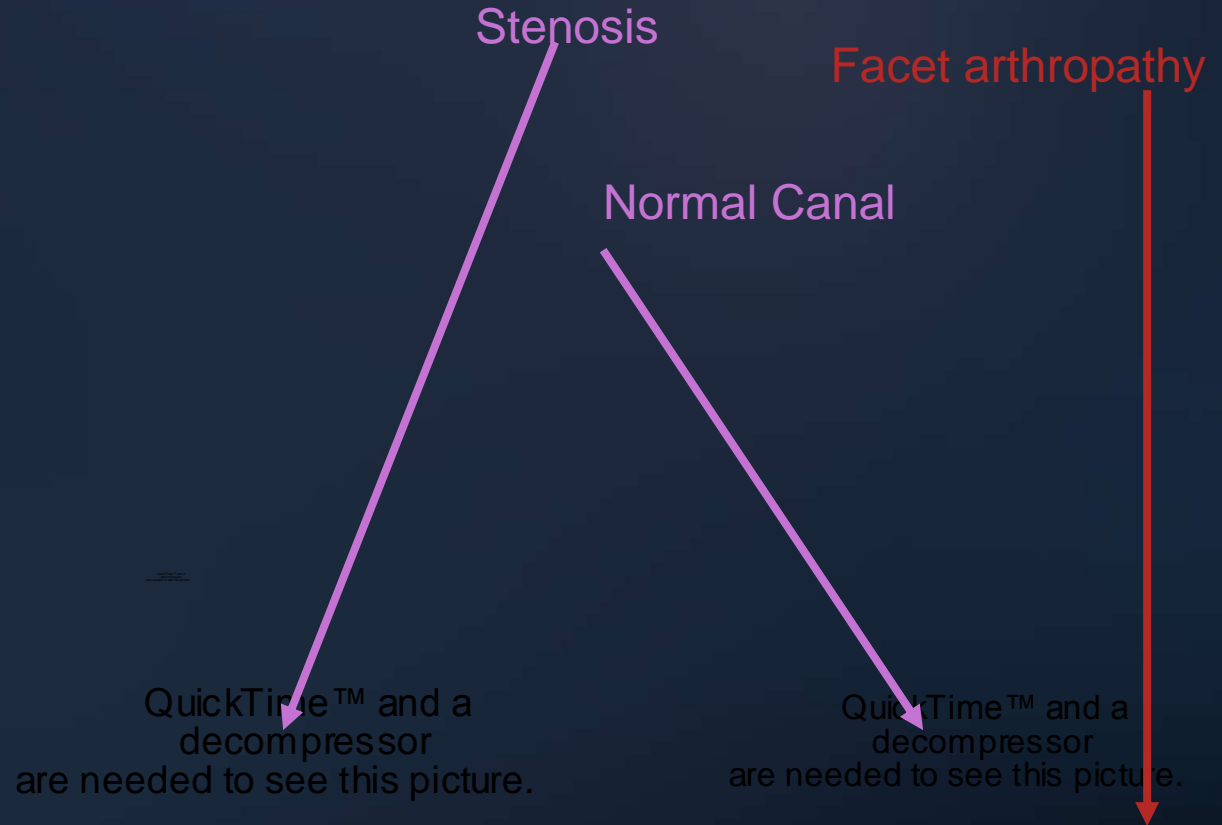
CASE 1: 46 YO FEMALE, JEHOVAH WITNESS,
NEUROGENIC CLAUDICATION, H/O INFX REQUIRED
MULTIPLE I&D - **POSTERIOR DECOMPRESSION**

QuickTime™ and a
decompressor
are needed to see this picture.

QuickTime™ and a
decompressor
are needed to see this picture.

CASE 1: 46 YO FEMALE, JEHOVAH WITNESS,
NEUROGENIC CLAUDICATION, H/O INFX REQUIRED
MULTIPLE I&D - POST-OP X-RAY

CASE 2 : 64 YEAR OLD FEMALE WITH SCOLIOSIS, SPONDYLOLISTHESIS, STENOSIS WITH BACK/LEG PAIN



CASE 2 : 64 YEAR OLD FEMALE WITH SCOLIOSIS, SPONDYLOLISTHESIS, STENOSIS WITH BACK/LEG PAIN

QuickTime™ and a
decompressor
are needed to see this picture.

QuickTime™ and a
decompressor
are needed to see this picture.

CASE 2 : 64 YEAR OLD FEMALE WITH SCOLIOSIS, SPONDYLOLISTHESIS, STENOSIS WITH BACK/LEG PAIN



CASE 3: 46 YO FEMALE, FAILED TDR, POST-OP INFECTION, DVT; SEVERE BACK AND LEG PAIN



QuickTime™ and a
decompressor
are needed to see this picture.

QuickTime™ and a
decompressor
are needed to see this picture.

CASE 3: 46 YO FEMALE, FAILED TDR, POST-OP INFECTION, DVT; SEVERE BACK AND LEG PAIN

QuickTime™ and a decompressor are needed to see this picture.

QuickTime™ and a decompressor are needed to see this picture.

QuickTime™ and a decompressor are needed to see this picture.

QuickTime™ and a decompressor are needed to see this picture.

QuickTime™ and a decompressor are needed to see this picture.

CASE 3: 46 YO FEMALE, FAILED TDR, POST-OP INFECTION, DVT; SEVERE BACK AND LEG PAIN

QuickTime™ and a decompressor are needed to see this picture.

QuickTime™ and a decompressor are needed to see this picture.

QuickTime™ and a decompressor are needed to see this picture.

CASE 3: 46 YO FEMALE, FAILED TDR, POST-OP INFECTION, DVT; SEVERE BACK AND LEG PAIN



QuickTime™ and a
decompressor
are needed to see this picture.

QuickTime™ and a
decompressor
are needed to see this picture.

CASE 4: 54 YO RT INSTRUCTOR, BROKEN FACET REPLACEMENT; BACK AND LEFT HIP PAIN. PATIENT 265 LBS

QuickTime™ and a
decompressor
are needed to see this picture.

QuickTime™ and a
decompressor
are needed to see this picture.

QuickTime™ and a
decompressor
are needed to see this picture.

stenosis

Facet arthropathy
W/ distraction

spondylolisthesis



CASE 4: 54 YO RT INSTRUCTOR, BROKEN FACET
REPLACEMENT; BACK AND LEFT HIP PAIN.
PATIENT 265 LBS

QuickTime™ and a
decompressor
are needed to see this picture.

QuickTime™ and a
decompressor
are needed to see this picture.

CASE 4: 54 YO RT INSTRUCTOR, BROKEN FACET REPLACEMENT; BACK AND LEFT HIP PAIN. PATIENT 265 LBS

QuickTime™ and a
decompressor
are needed to see this picture.



Broken cemented
Stem of TFR



CASE 4: 54 YO RT INSTRUCTOR, BROKEN FACET
REPLACEMENT; BACK AND LEFT HIP PAIN.
PATIENT 265 LBS

QuickTime™ and a
decompressor
are needed to see this picture.

QuickTime™ and a
decompressor
are needed to see this picture.

CASE 4: 54 YO RT INSTRUCTOR, BROKEN FACET
REPLACEMENT; BACK AND LEFT HIP PAIN.
PATIENT 265 LBS



QuickTime™ and a
decompressor
are needed to see this picture.

QuickTime™ and a
decompressor
are needed to see this picture.

CASE 4: 54 YO RT INSTRUCTOR, BROKEN FACET
REPLACEMENT; BACK AND LEFT HIP PAIN.
PATIENT 265 LBS



QuickTime™ and a
decompressor
are needed to see this picture.

QuickTime™ and a
decompressor
are needed to see this picture.

CASE 5



CONCLUSION

QuickTime™ and a
decompressor
are needed to see this picture.

- Less blood loss
- Less hospital stay
- Safer for patients
- Able to resolve complex issues

THANK YOU

QuickTime™ and a
decompressor
are needed to see this picture.