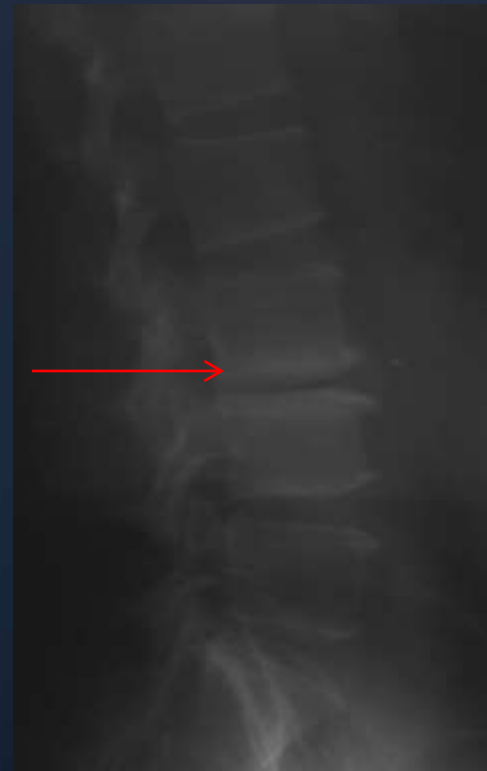
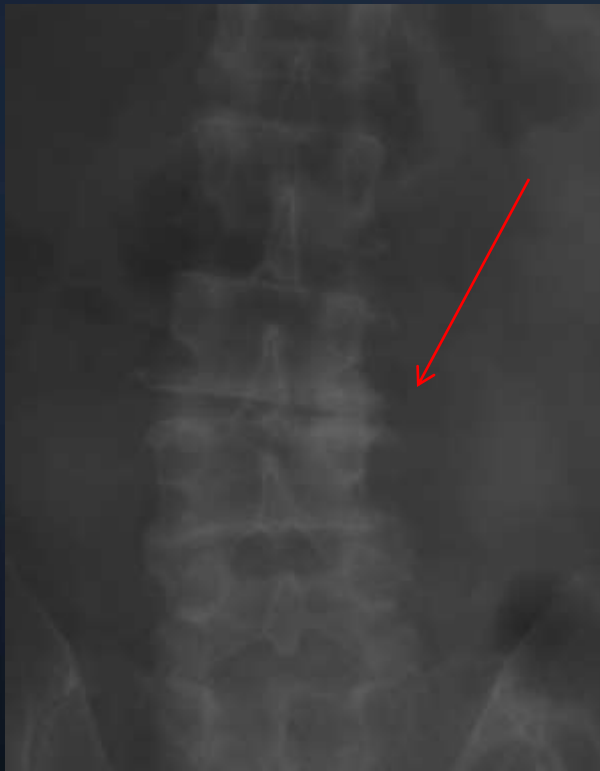
# APPLICATION OF TRANSPSOAS APPROACH

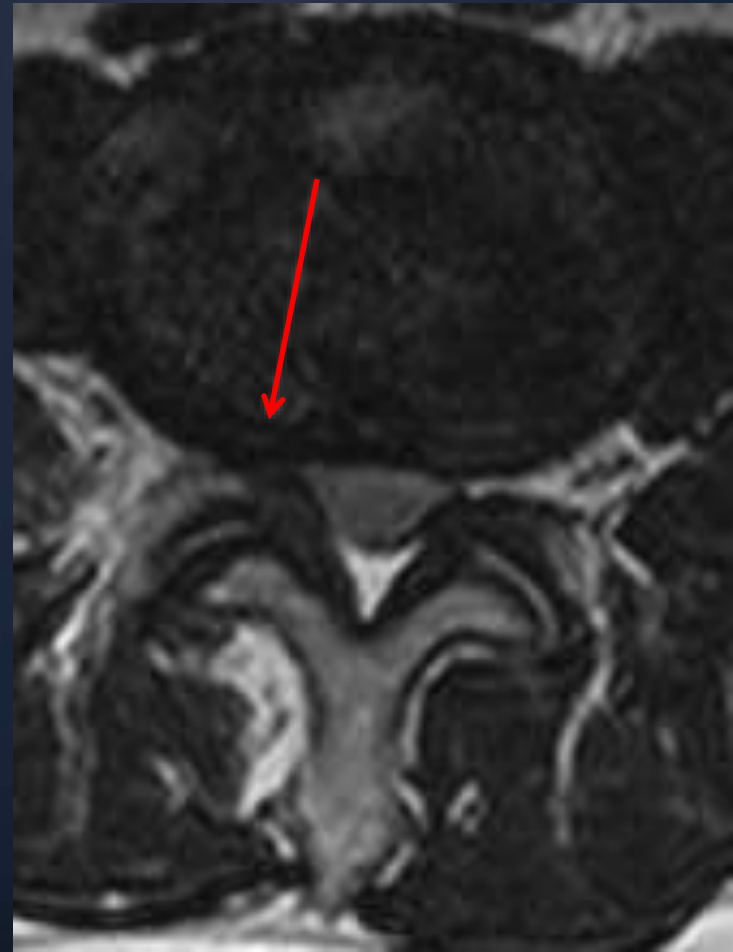
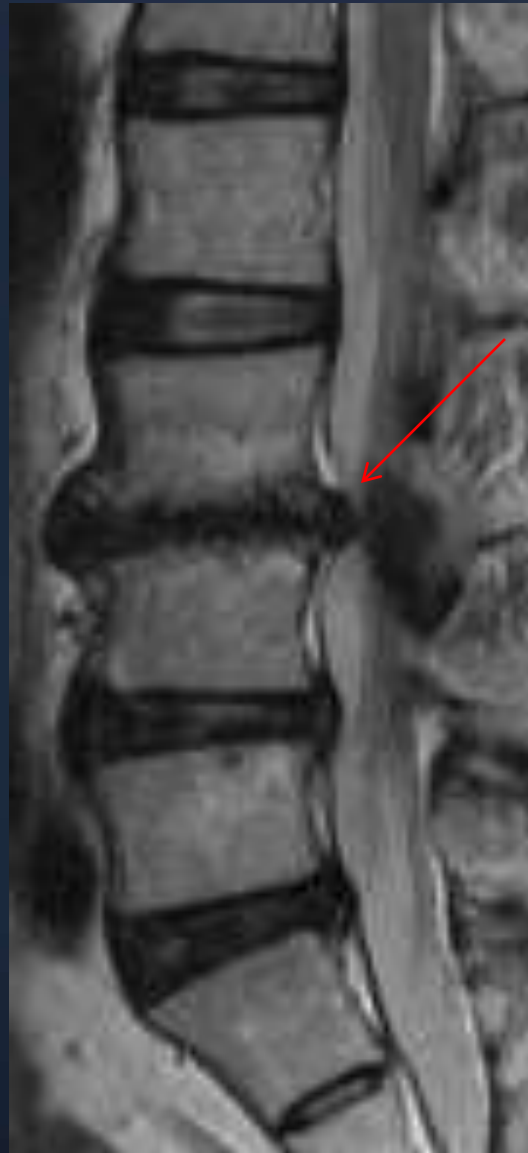
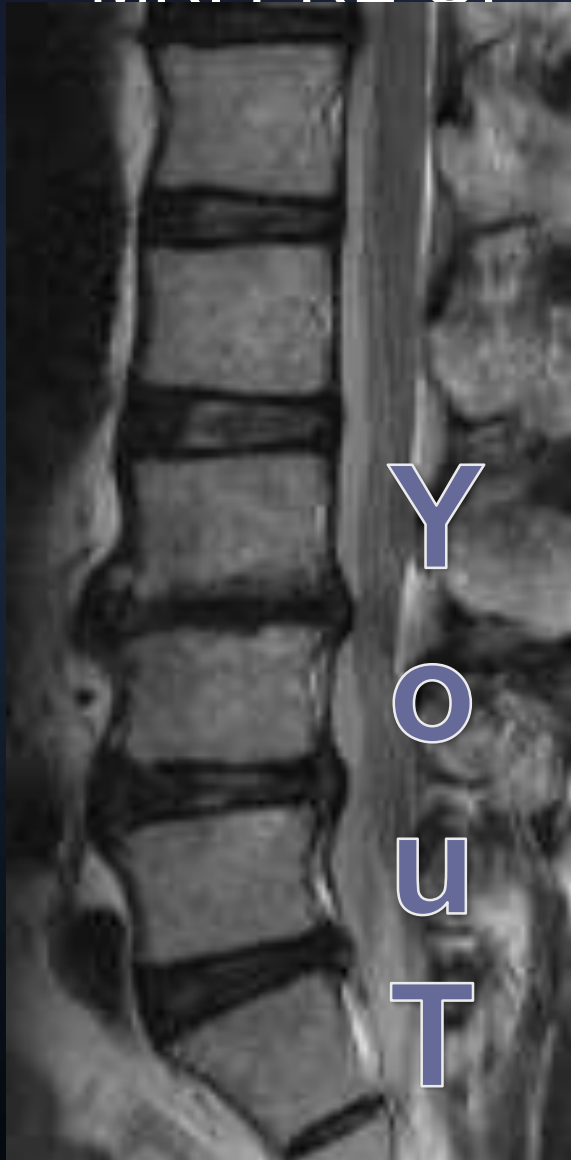WAYNE CHENG, MD

*BONES AND SPINE*

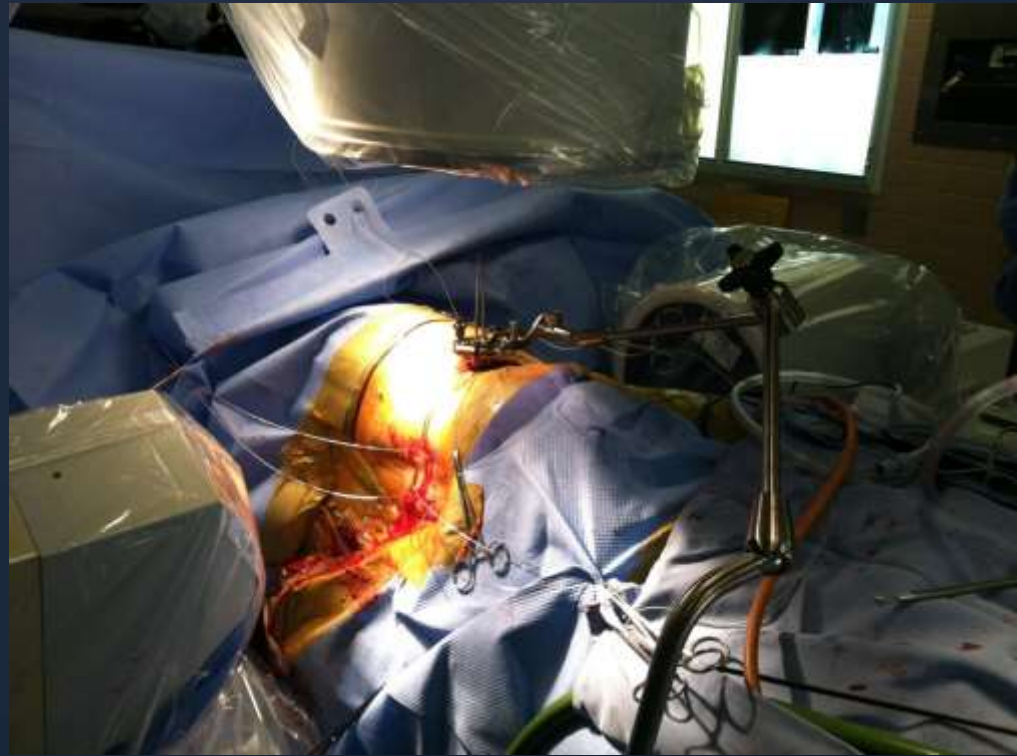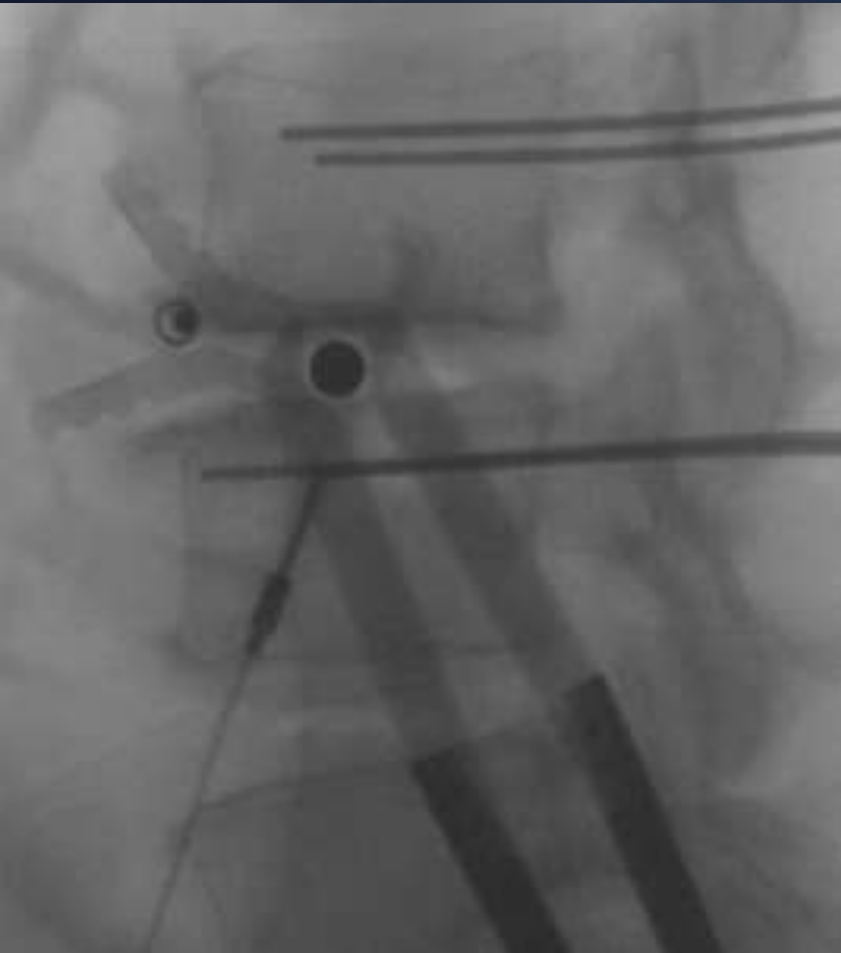# CASE 15 yo with lower back pain and right thigh pain



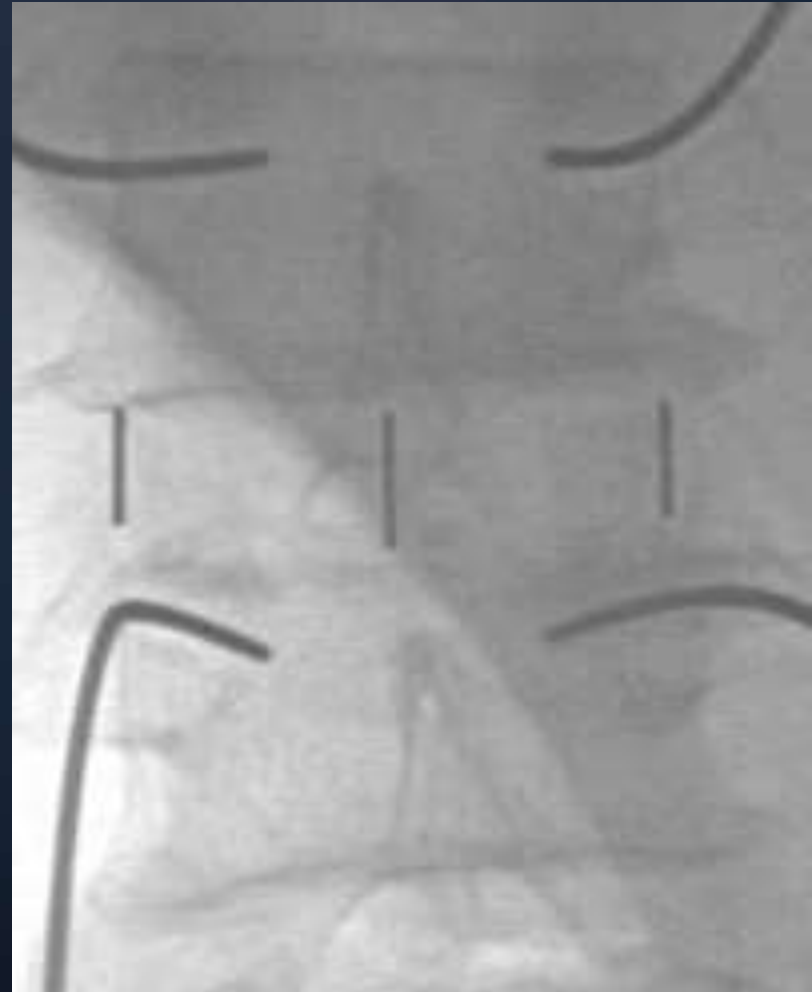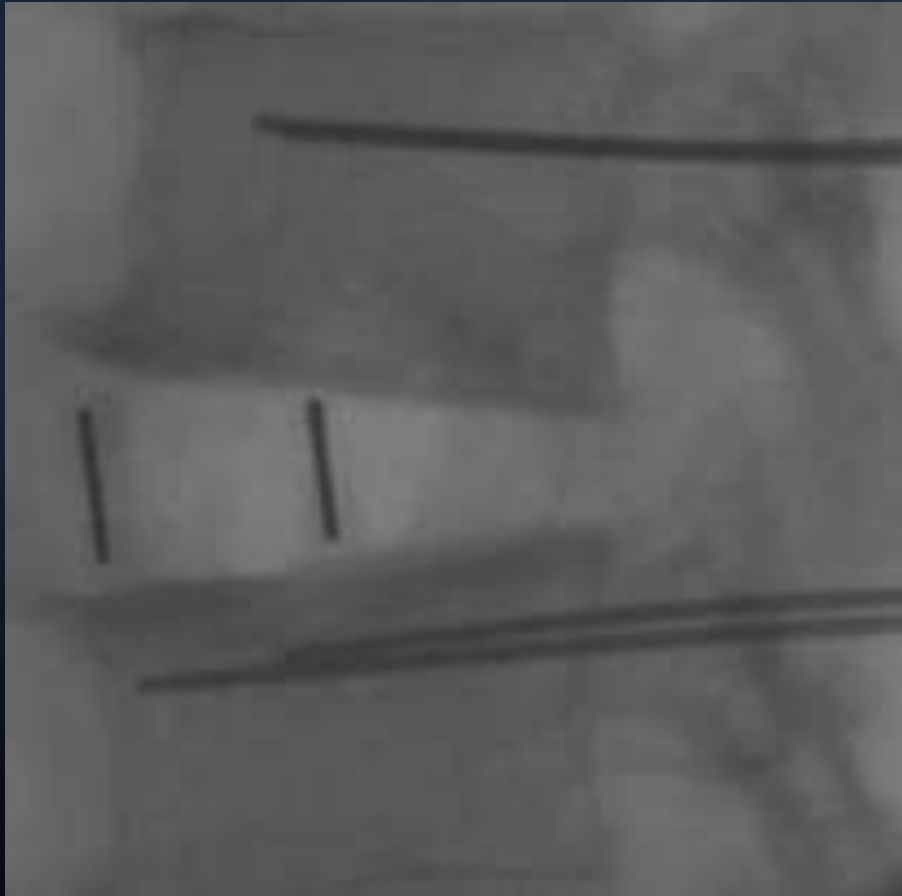# MRI PRE OP



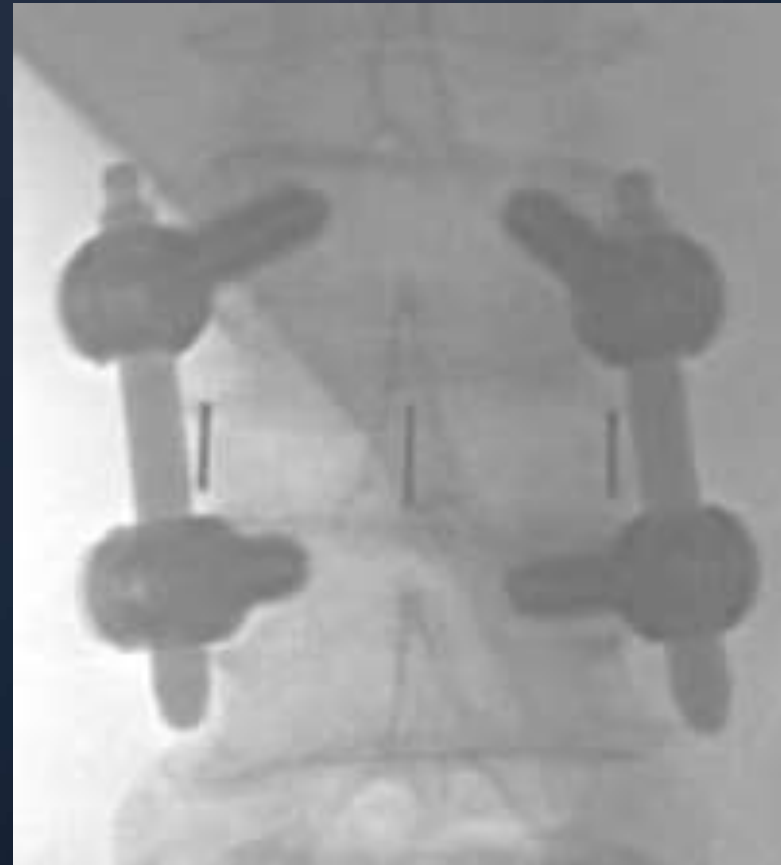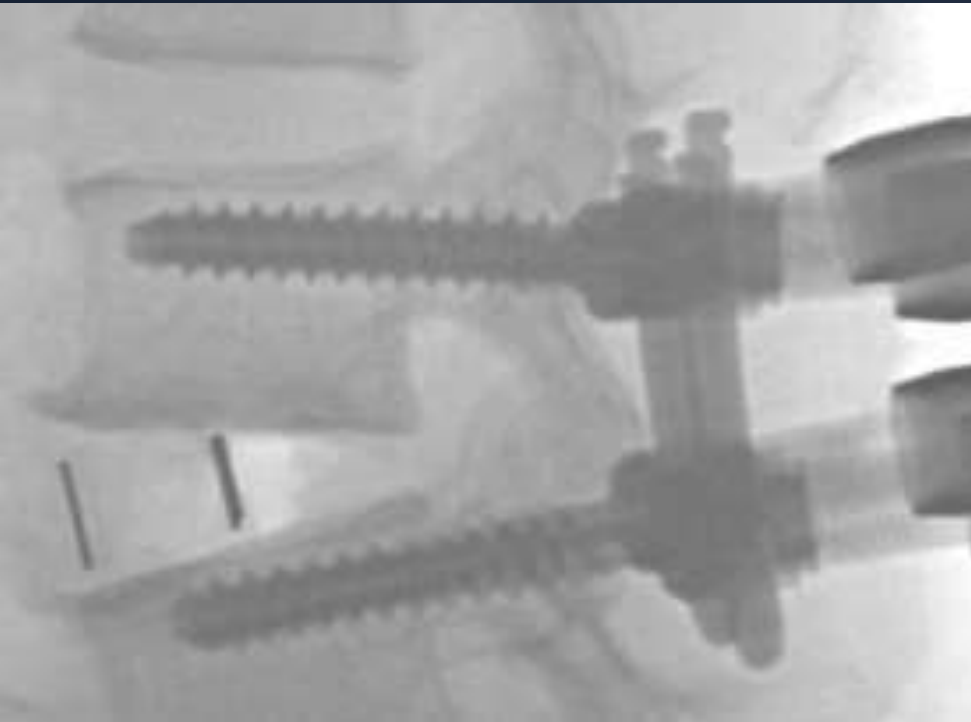# CASE 1 - INTRA OP



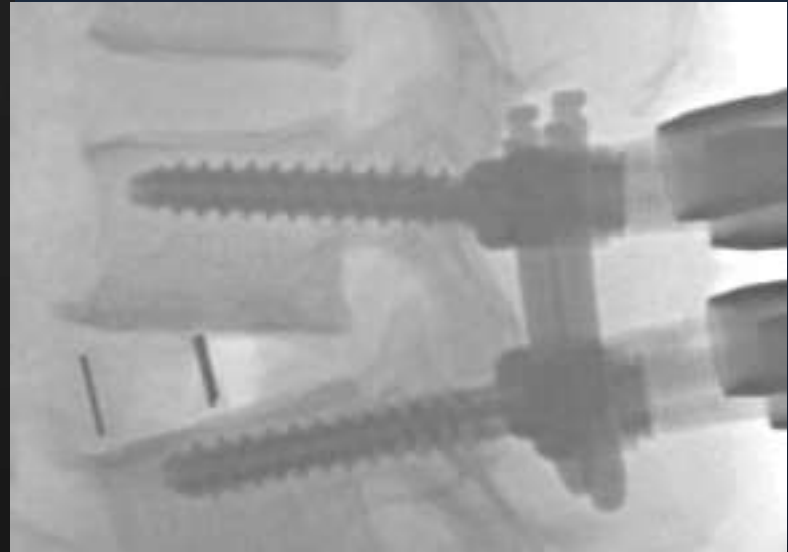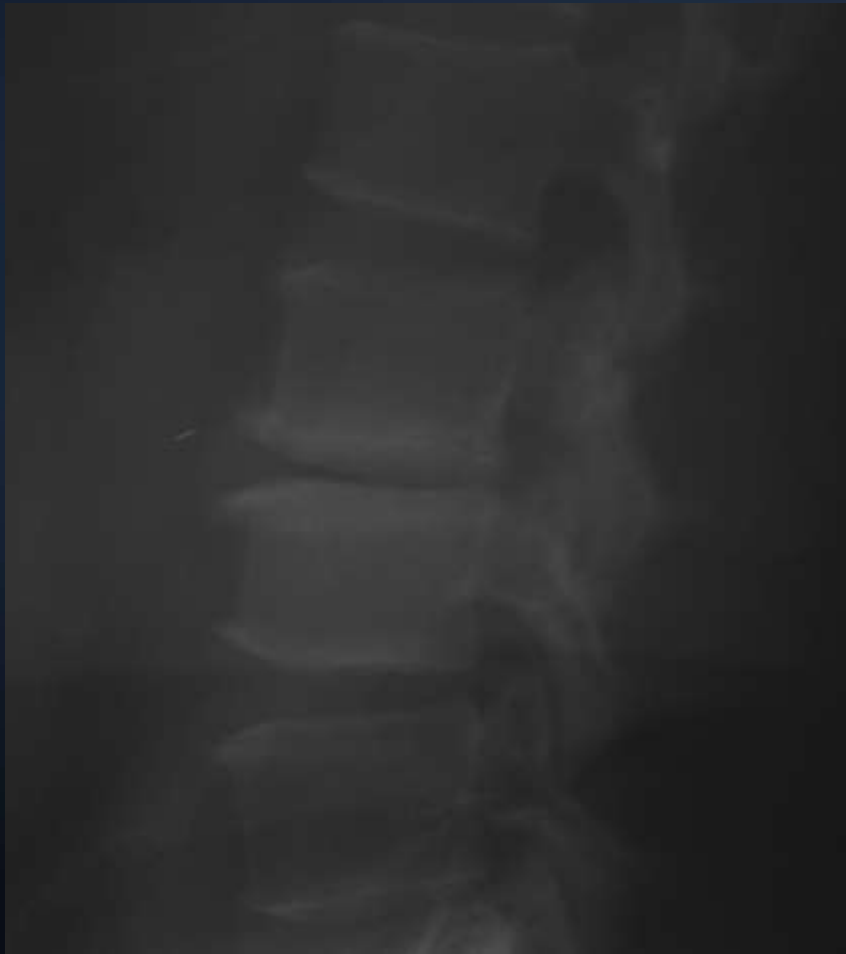# CASE 1- INTRA OP



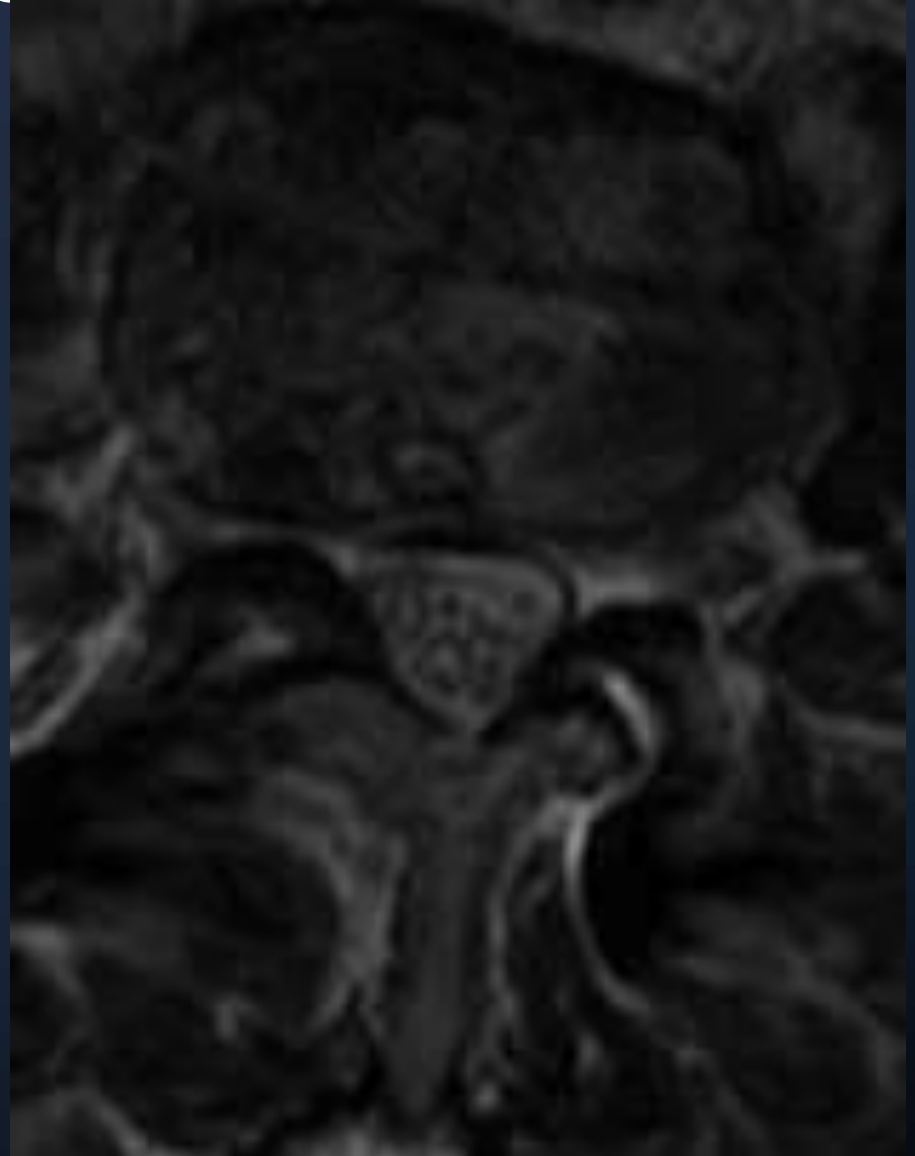
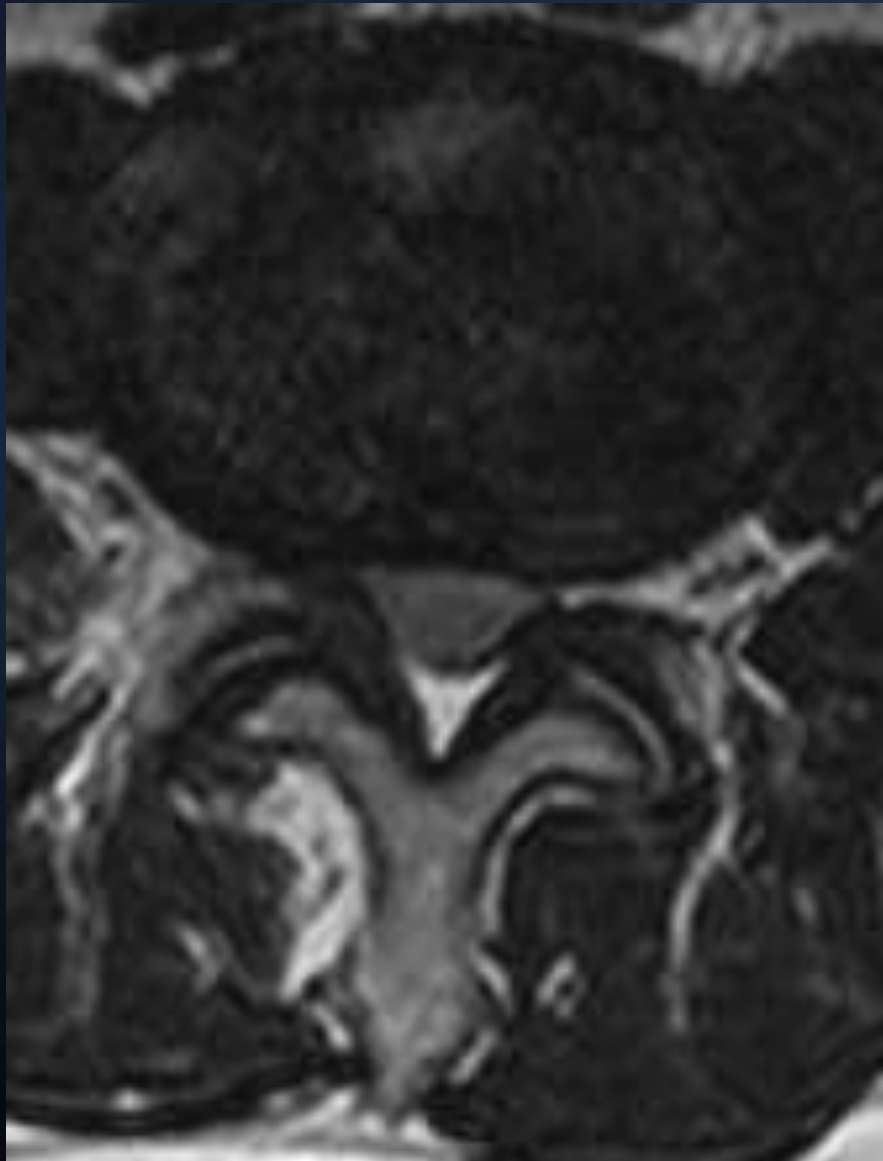
# CASE 1 INTRA OP



# CASE 1 – PRE AND POST OP XRAY

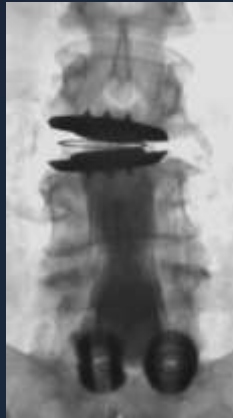

## CASE 1 – PRE AND POST OP MRI





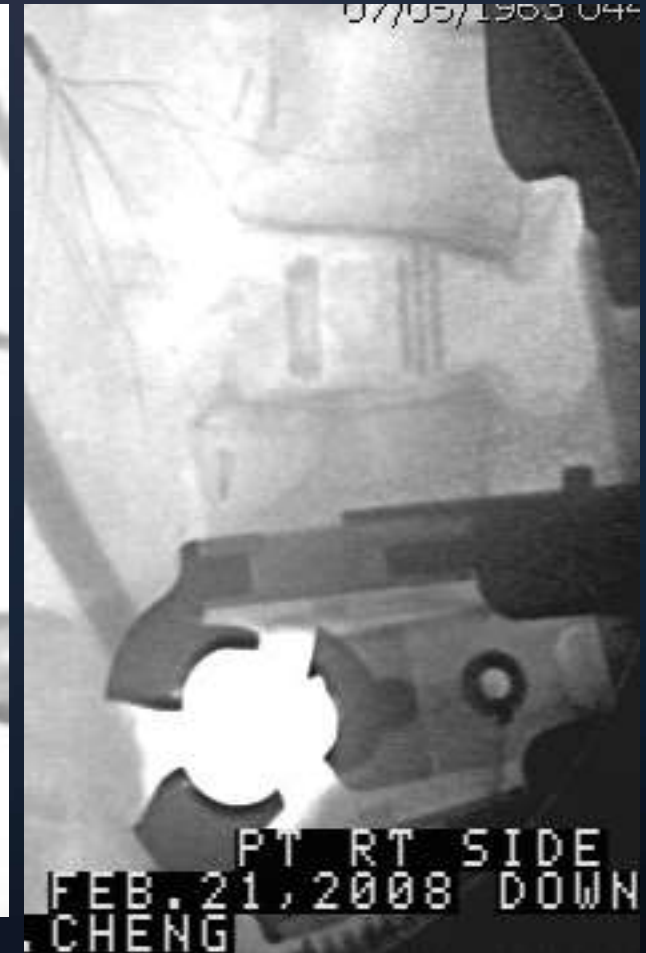
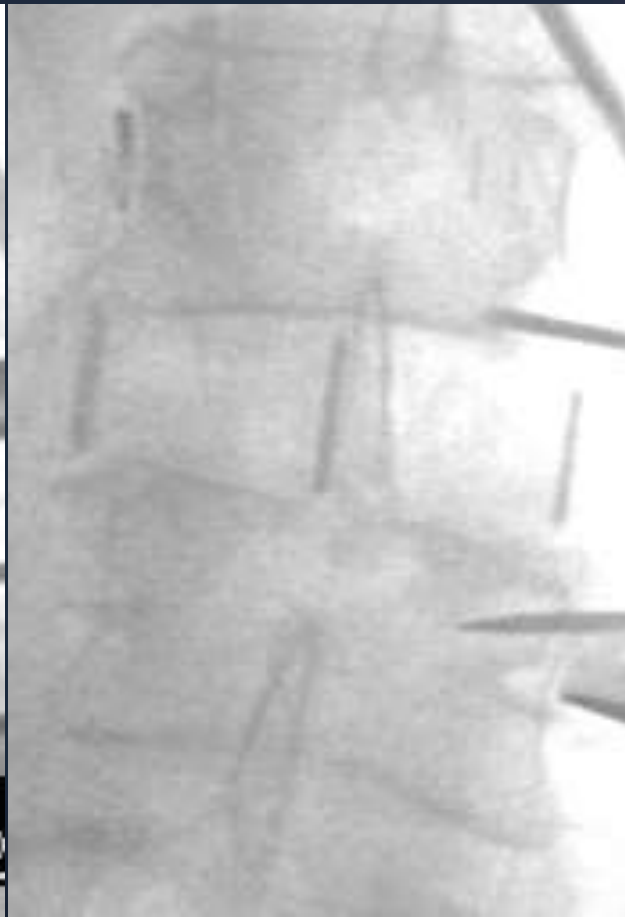
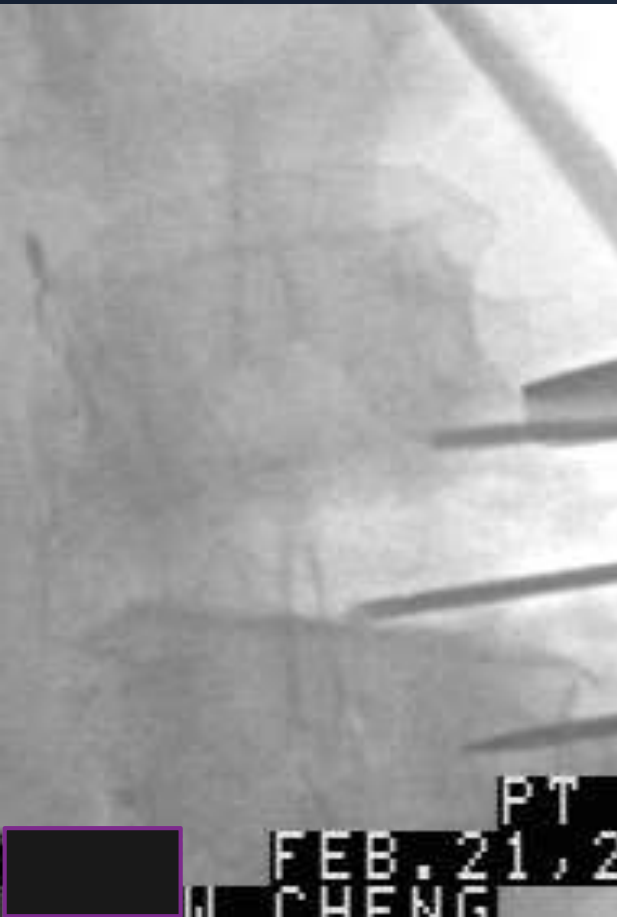
# CASE 2: 46 YO FEMALE, FAILED TDR, POST-OP INFECTION, DVT; SEVERE BACK AND LEG PAIN



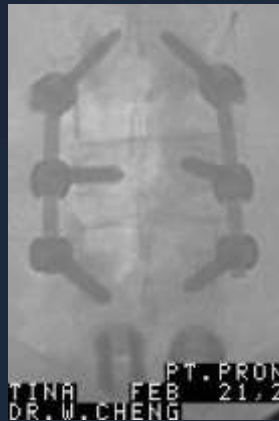# CASE 2: 46 YO FEMALE, FAILED TDR, POST-OP INFECTION, DVT; SEVERE BACK AND LEG PAIN



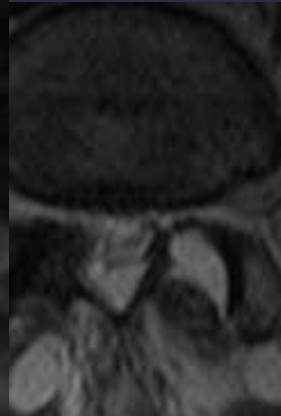
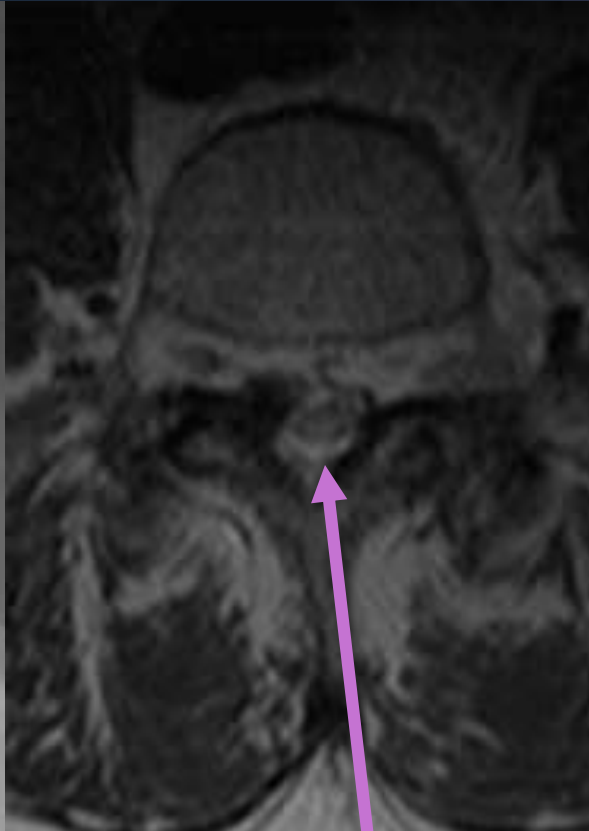
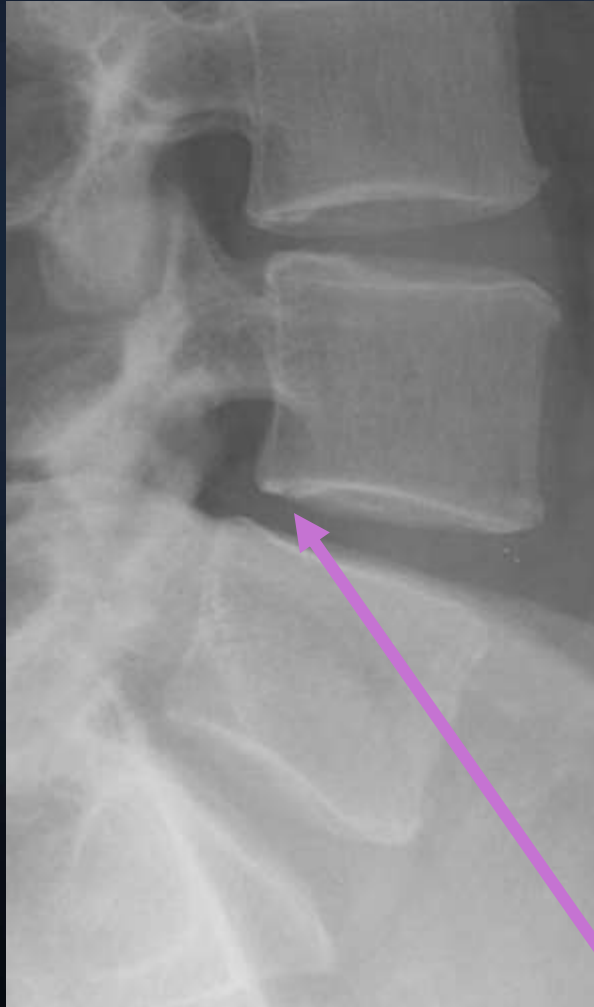# CASE 2: 46 YO FEMALE, FAILED TDR, POST-OP INFECTION, DVT; SEVERE BACK AND LEG PAIN



# CASE 2: 46 YO FEMALE, FAILED TDR, POST-OP INFECTION, DVT; SEVERE BACK AND LEG PAIN



# CASE 3: 54 YO RT INSTRUCTOR, BROKEN FACET REPLACEMENT; BACK AND LEFT HIP PAIN. PATIENT 265 LBS

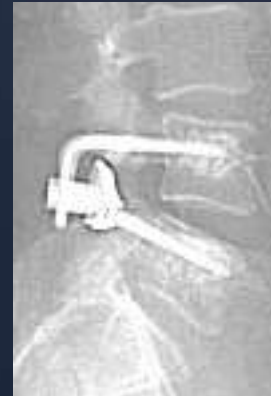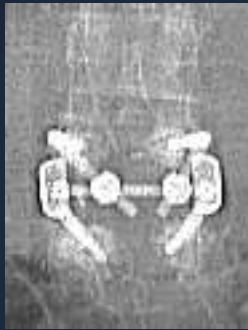


spondylolisthesis

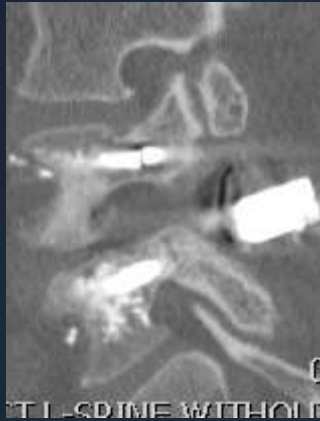stenosis

Facet arthropathy  
W/ distraction

CASE 3: 54 YO RT INSTRUCTOR, BROKEN FACET  
REPLACEMENT; BACK AND LEFT HIP PAIN.  
PATIENT 265 LBS

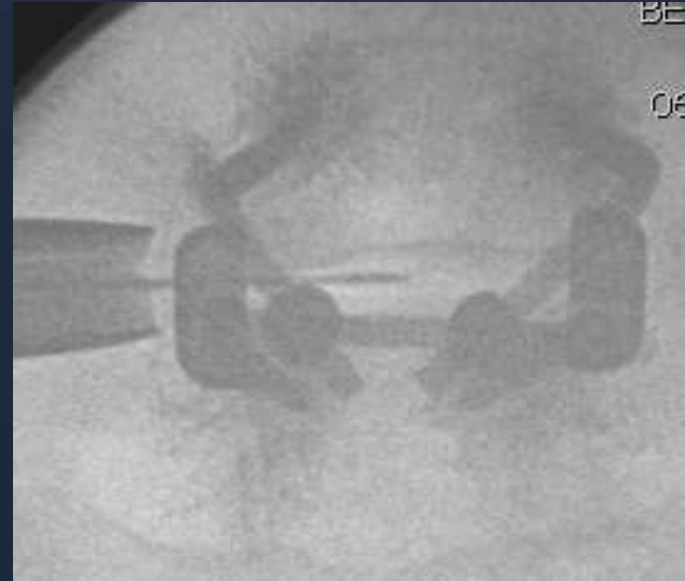
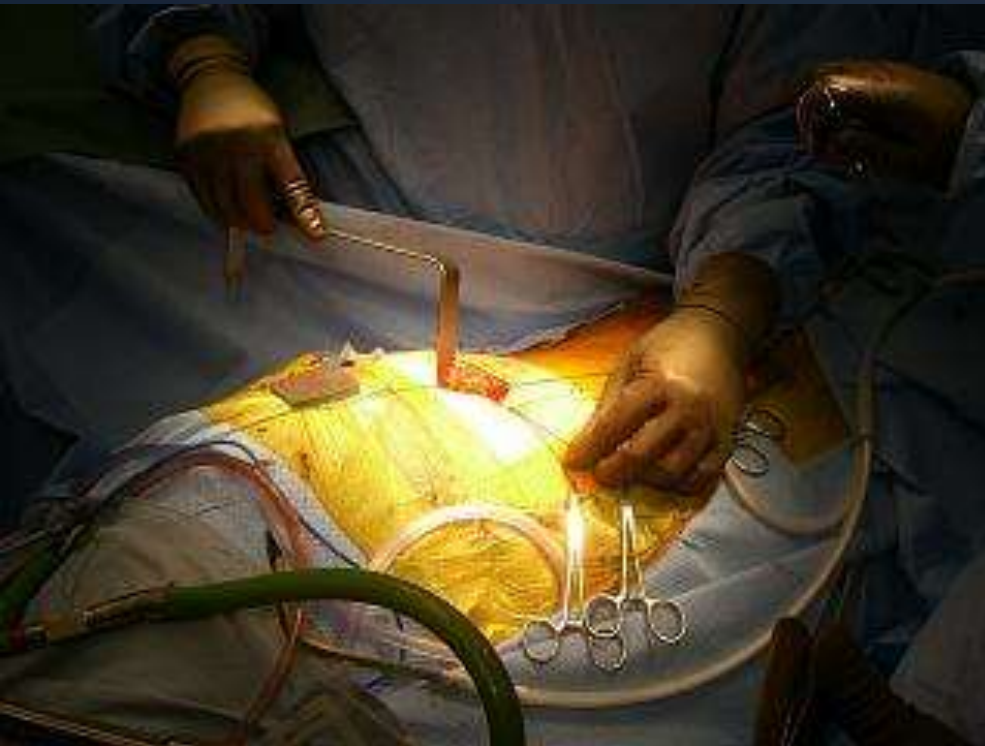

# CASE 3: 54 YO RT INSTRUCTOR, BROKEN FACET REPLACEMENT; BACK AND LEFT HIP PAIN. PATIENT 265 LBS



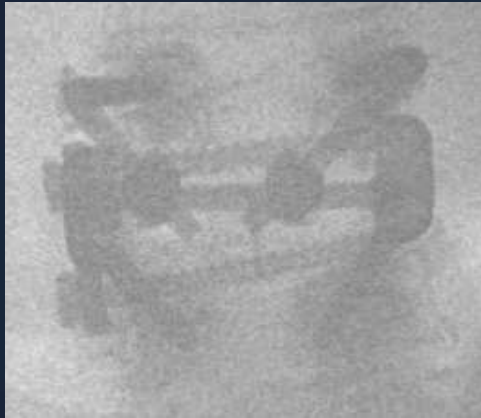Broken cemented  
Stem of THR

CASE 3: 54 YO RT INSTRUCTOR, BROKEN FACET  
REPLACEMENT; BACK AND LEFT HIP PAIN.  
PATIENT 265 LBS

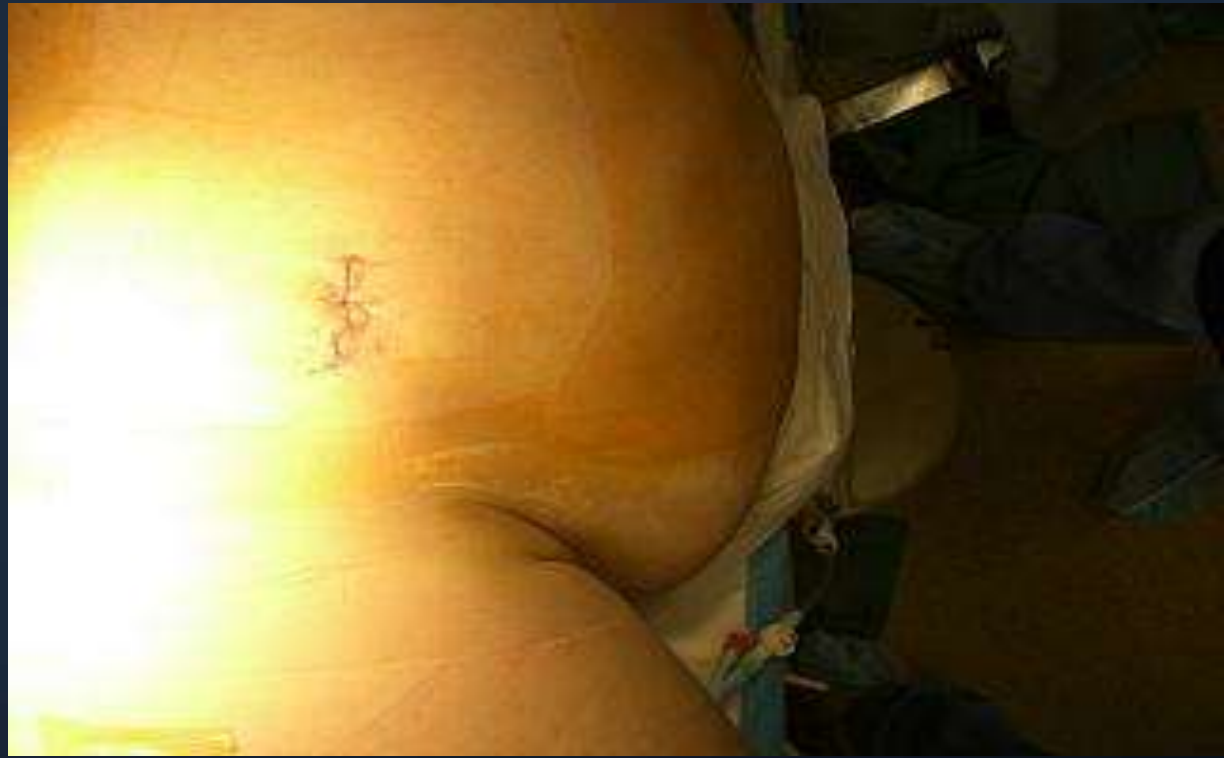
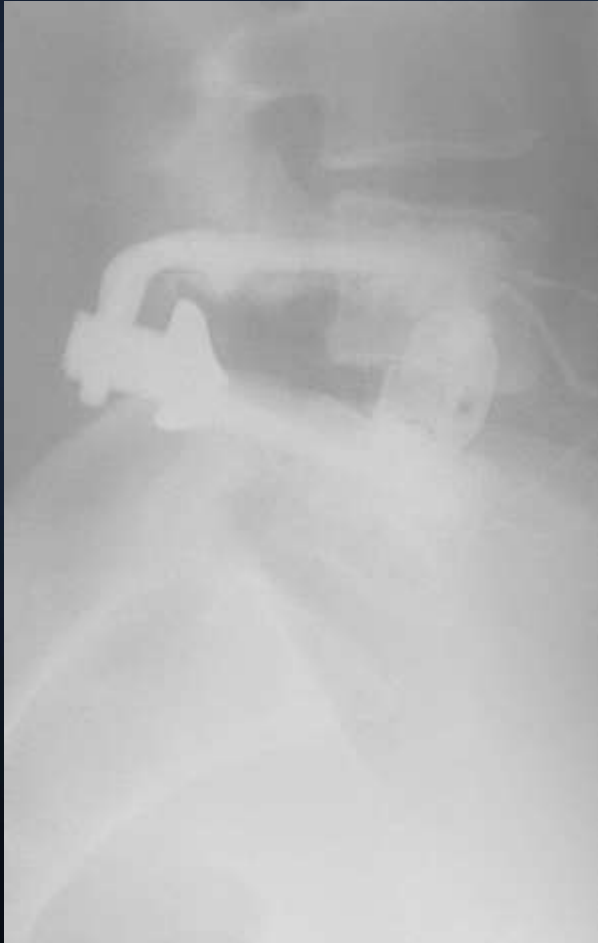


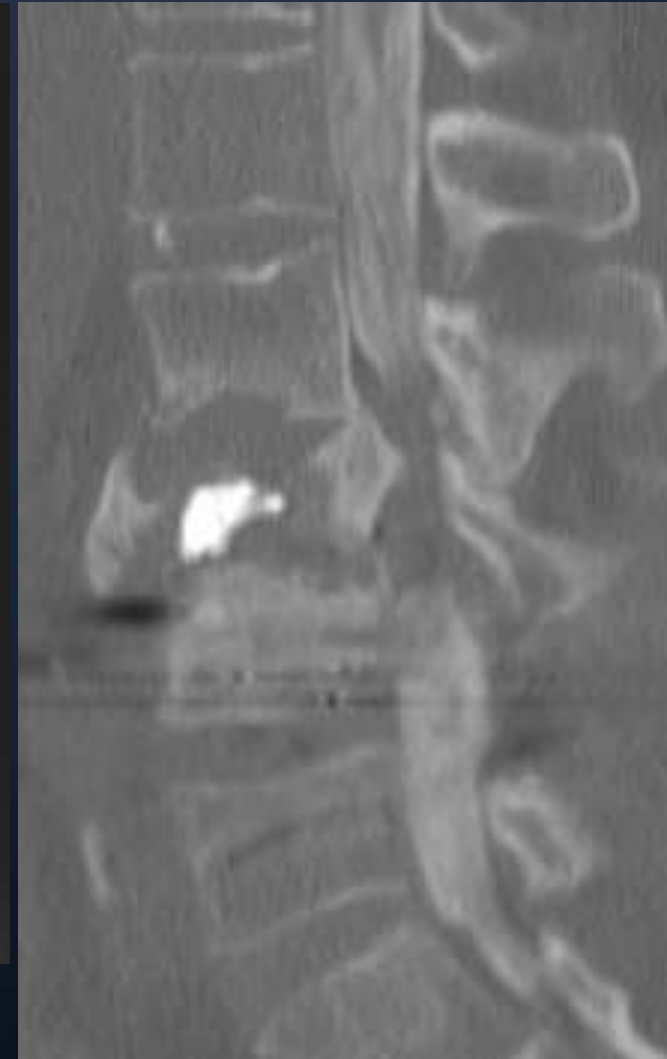
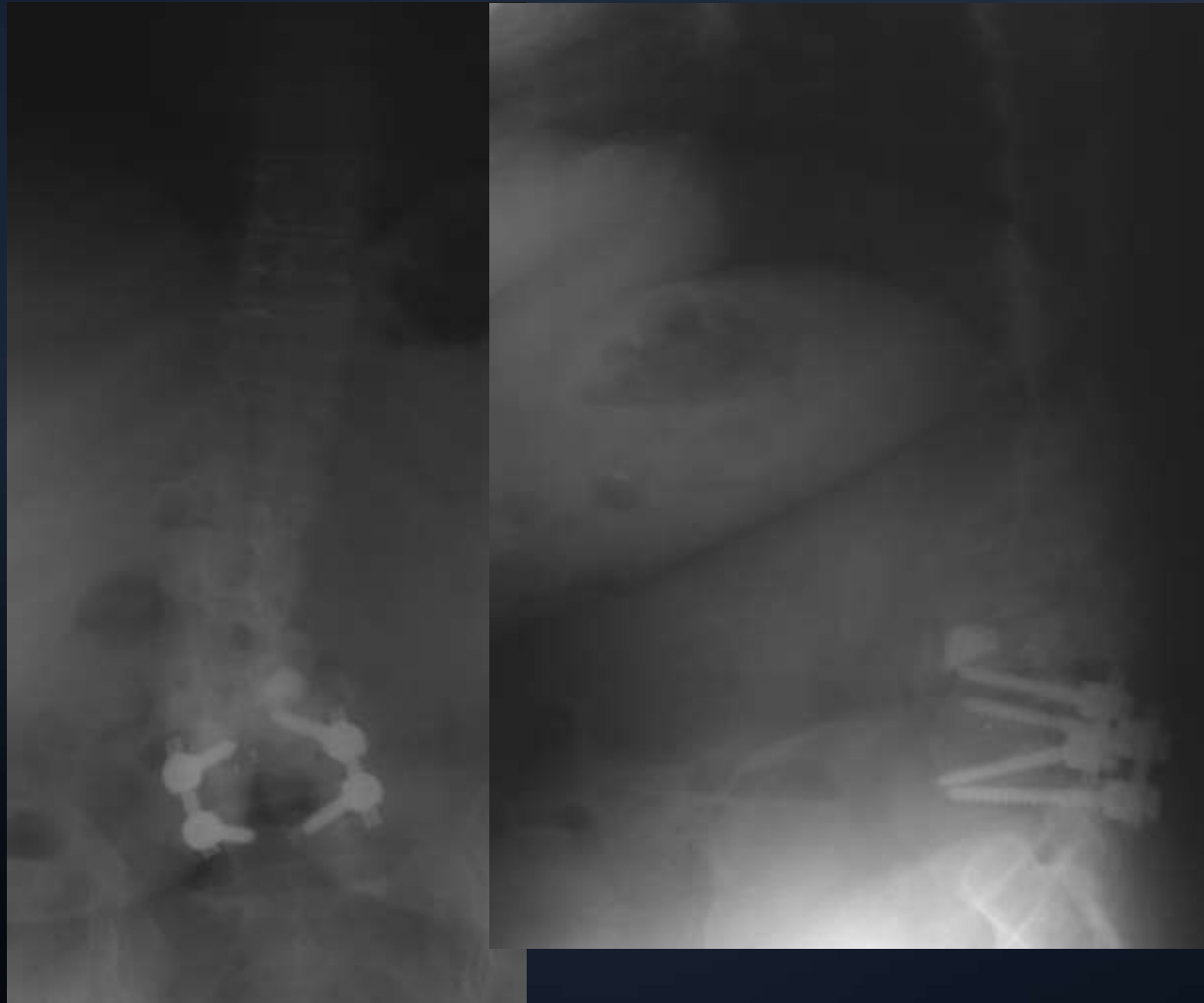CASE 3: 54 YO RT INSTRUCTOR, BROKEN FACET  
REPLACEMENT; BACK AND LEFT HIP PAIN.



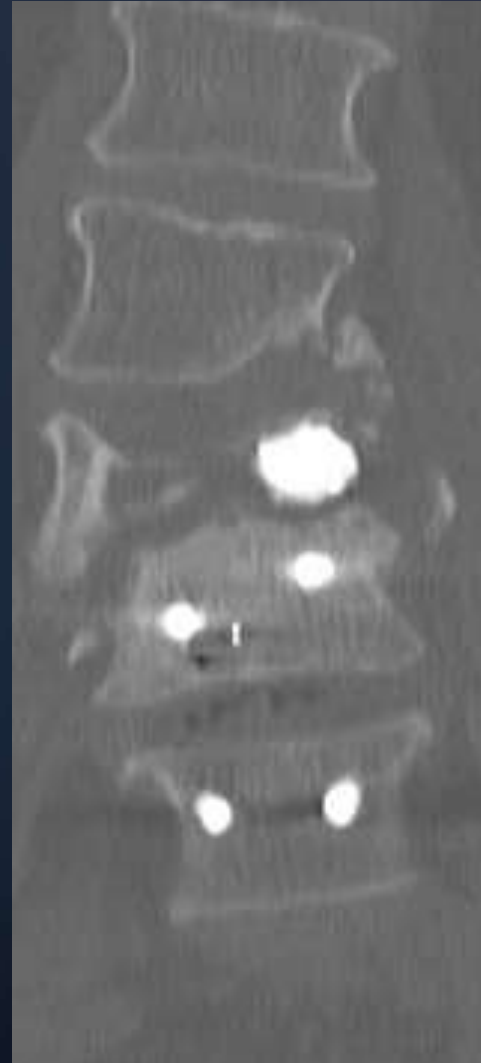
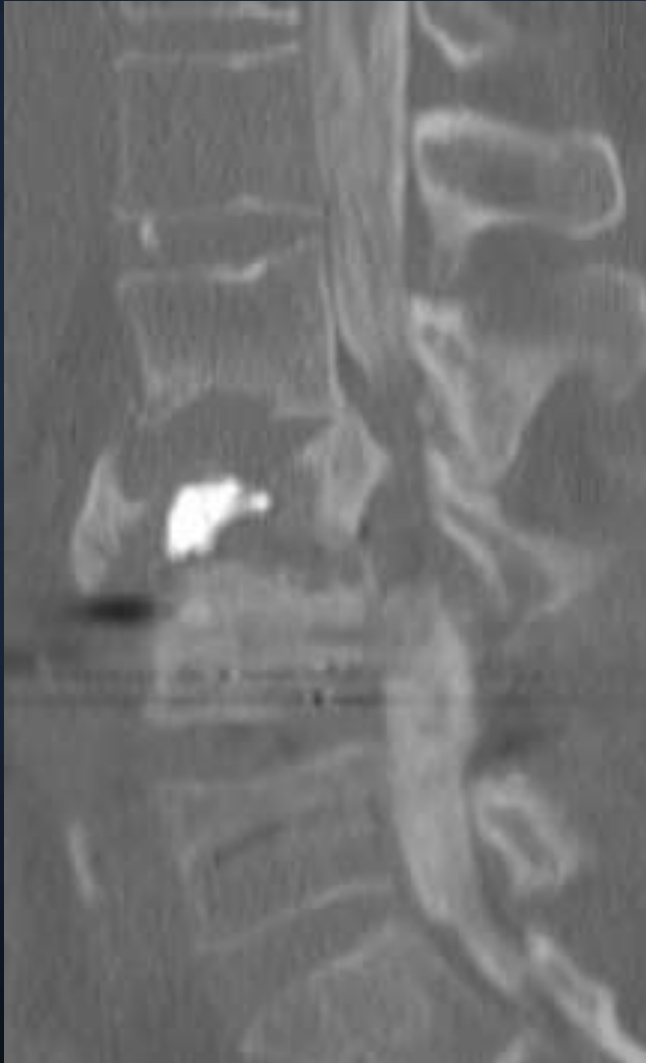CASE 3: 54 YO RT INSTRUCTOR, BROKEN FACET  
REPLACEMENT; BACK AND LEFT HIP PAIN.  
PATIENT 265 LBS



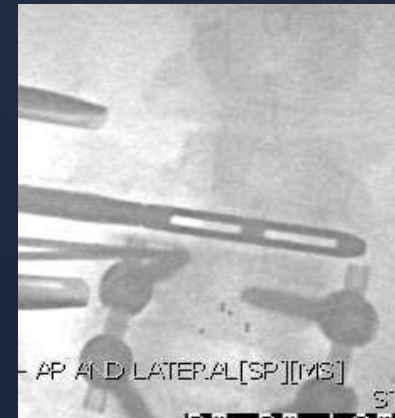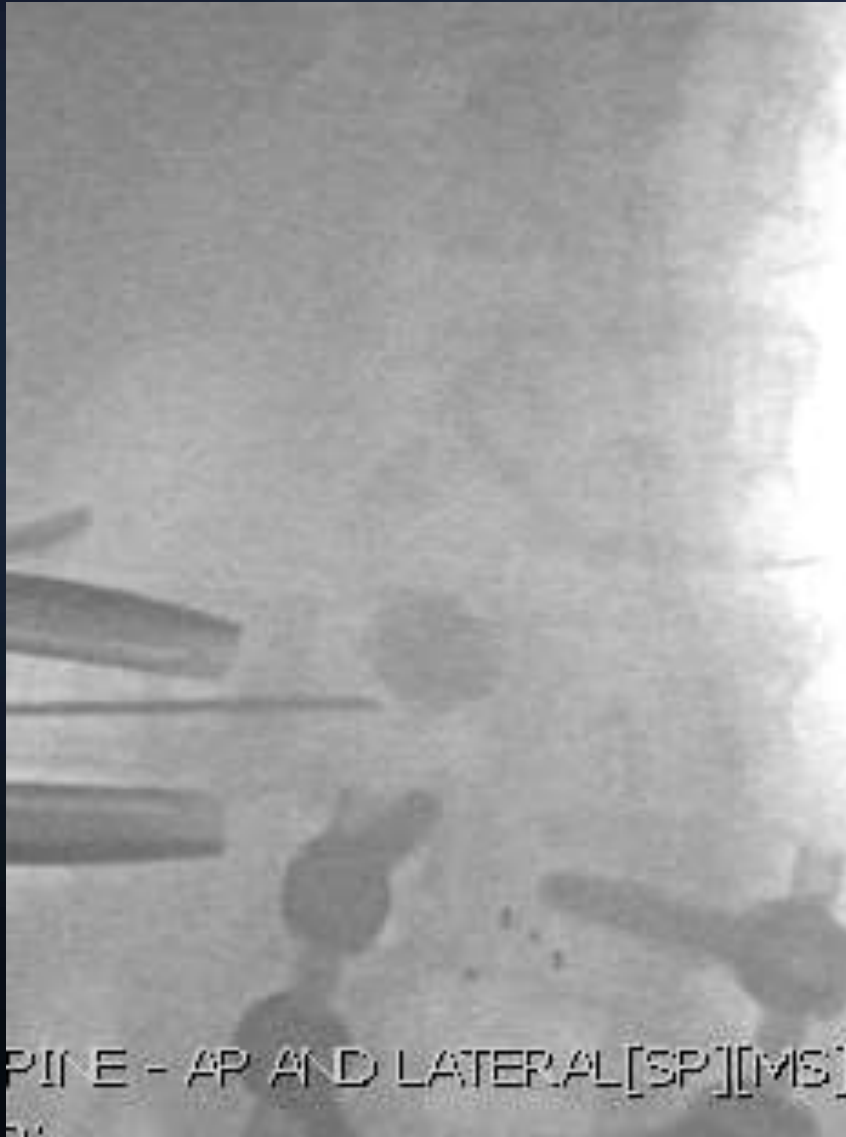
# CASE 4 – 59 YO F W BURST FX, FAILED KYPHO, 250#



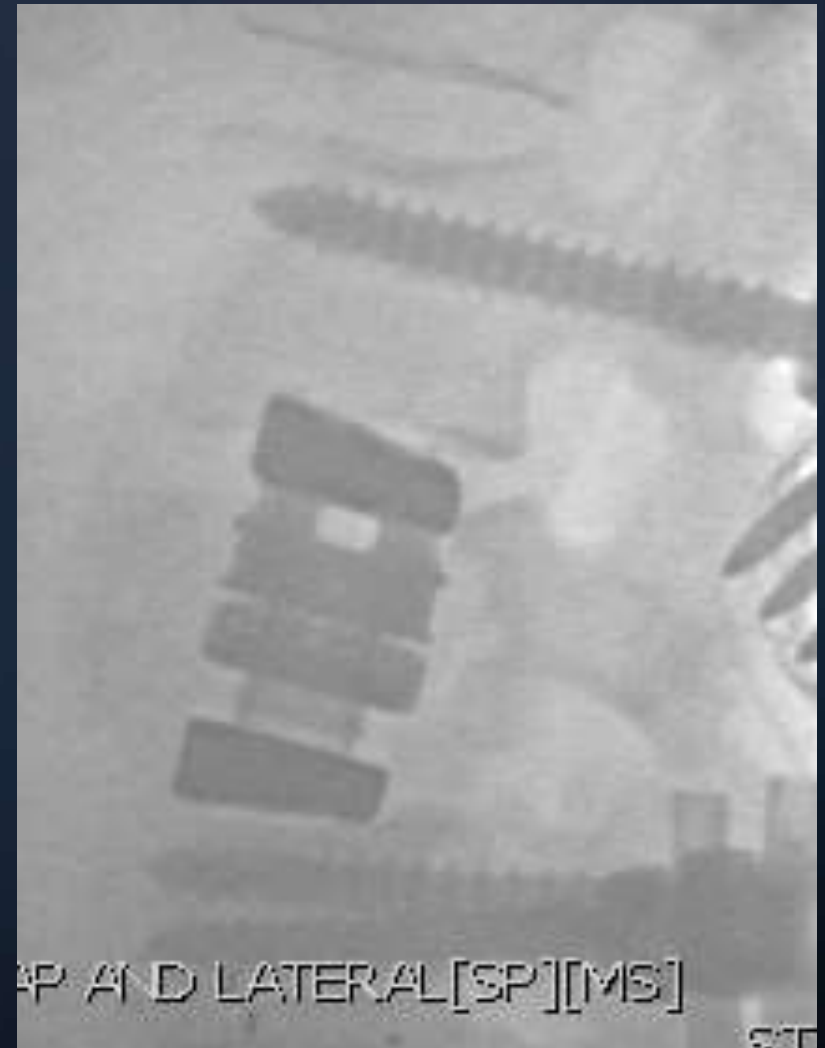# CASE 4 – 59 YO F W BURST FAILED KYPHO, 250#

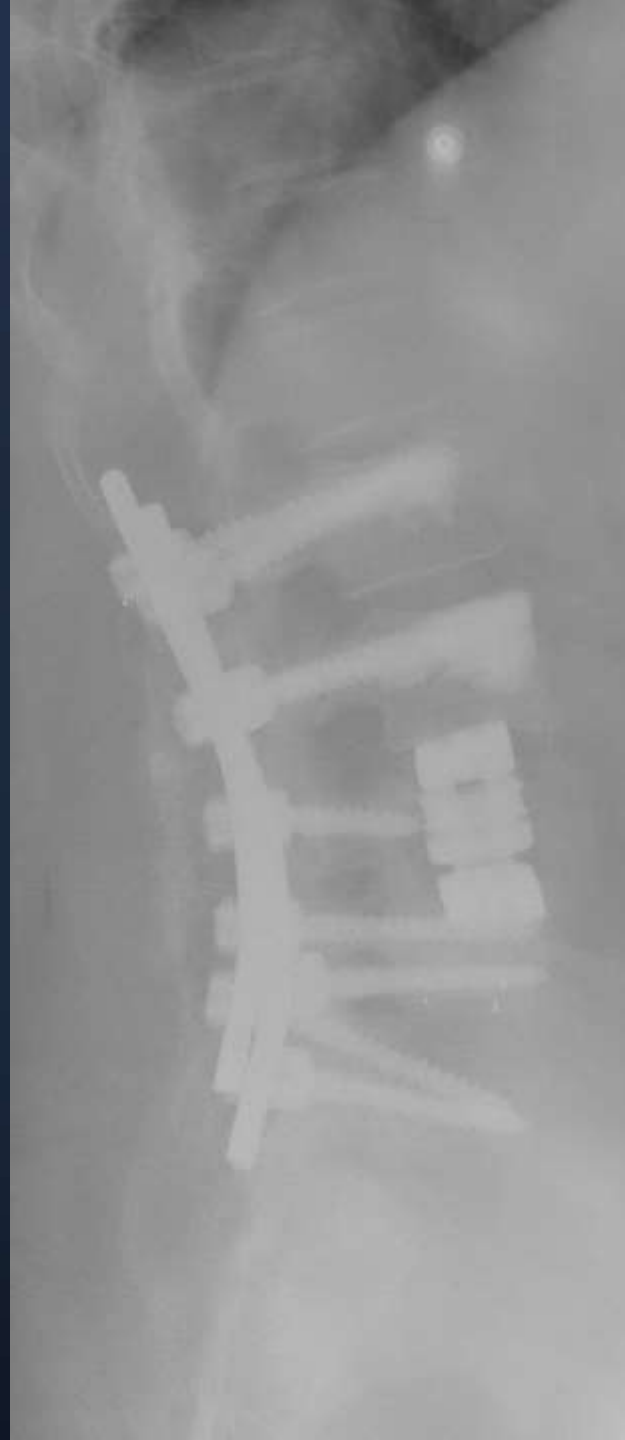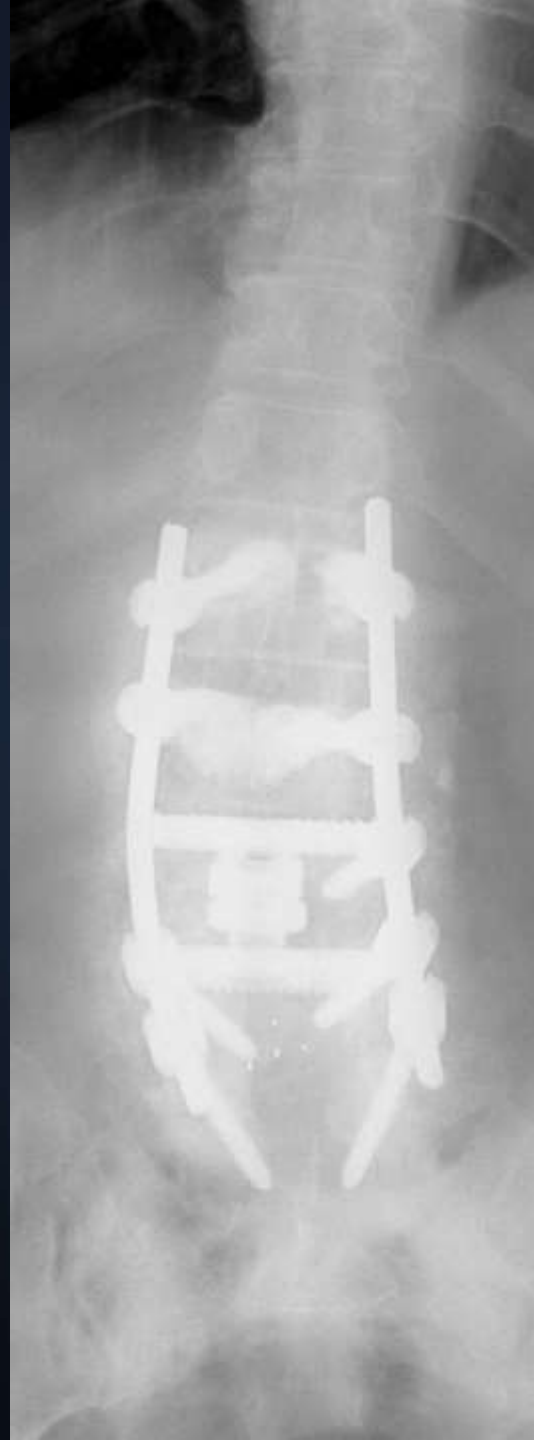


# 59 YO 250# F W BURST FX, FAILED VERTEBROPLASTY



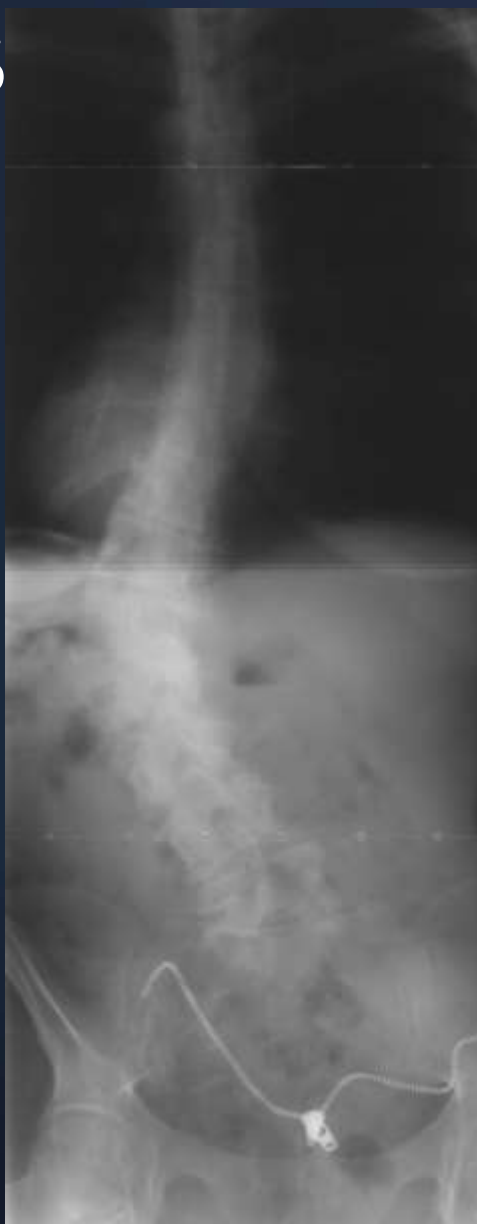
# 59 YO 250# F W BURST FX, FAILED VERTEBROPLASTY





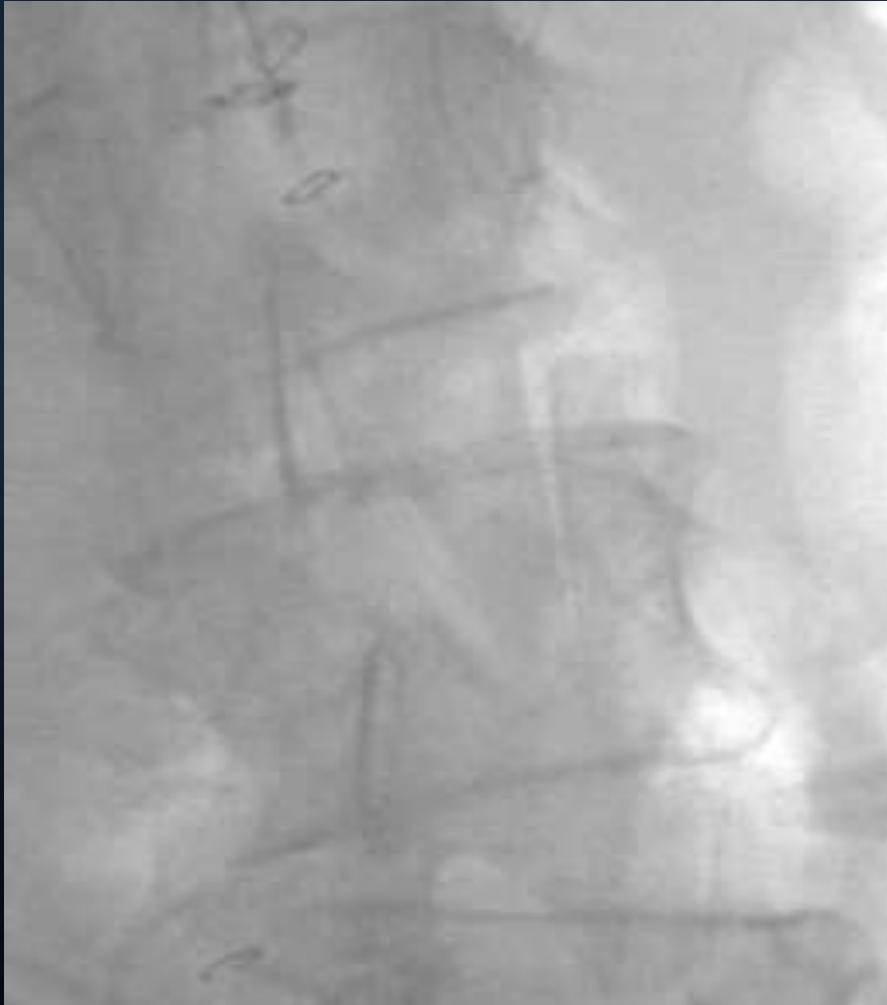CASE 5 - 55

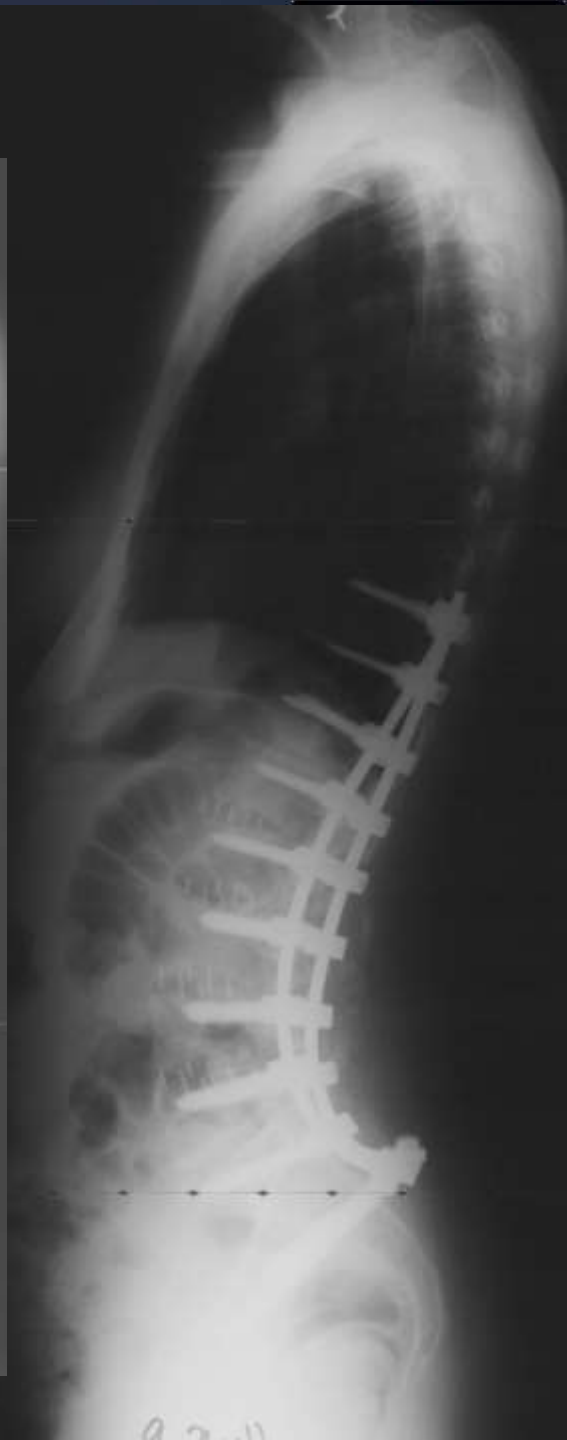
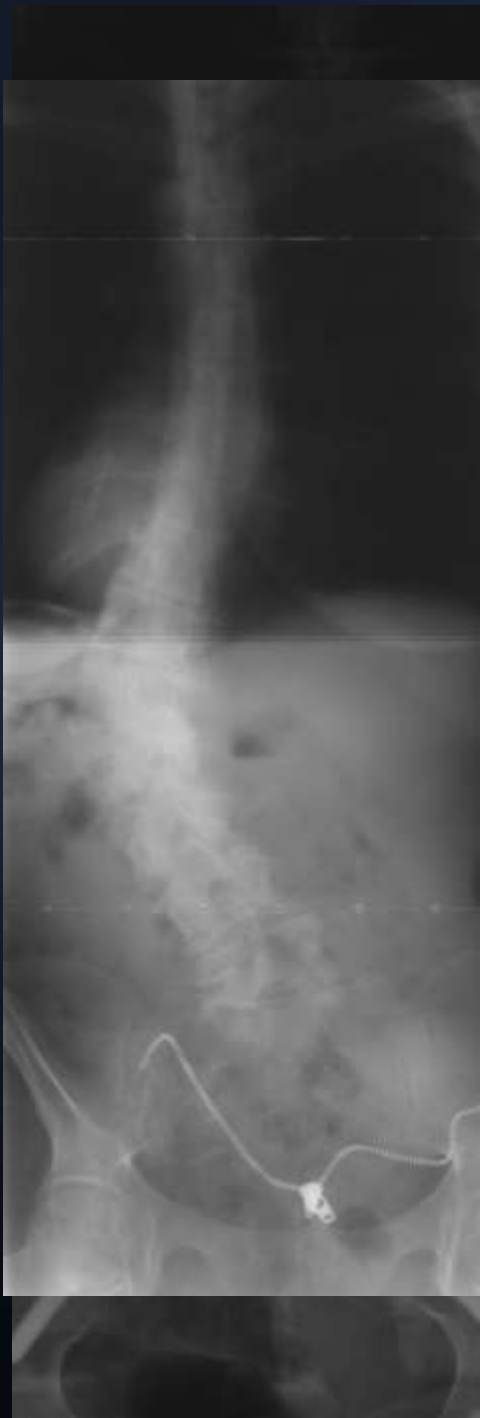SIS



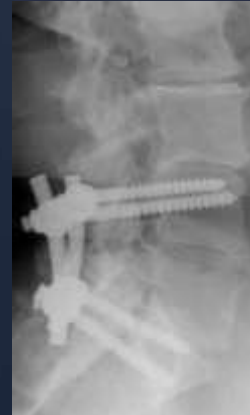
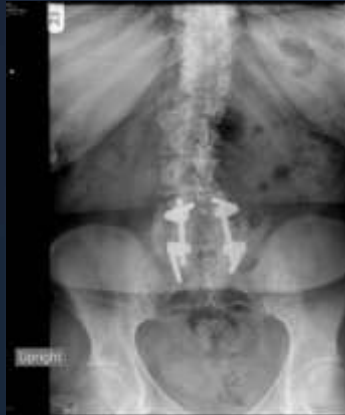
# 55 YO F W SCOLIOSIS

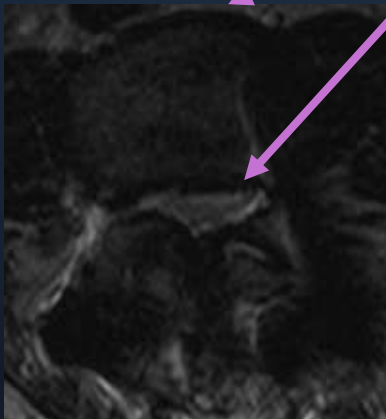
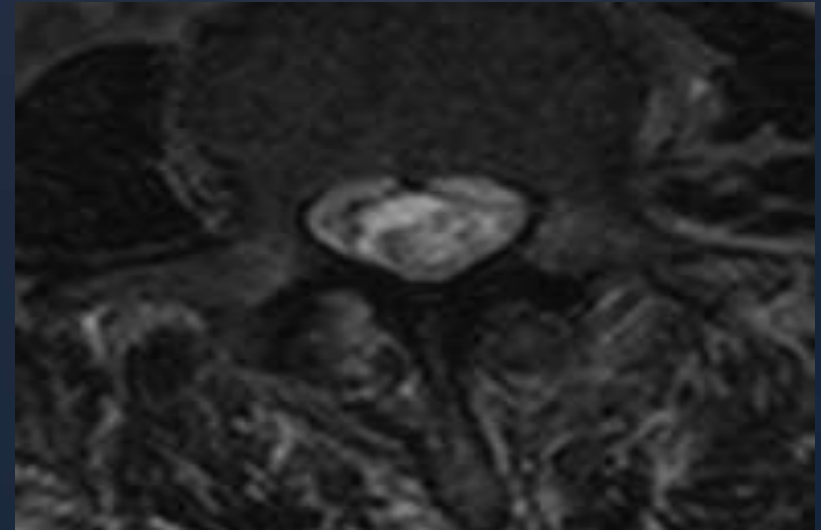
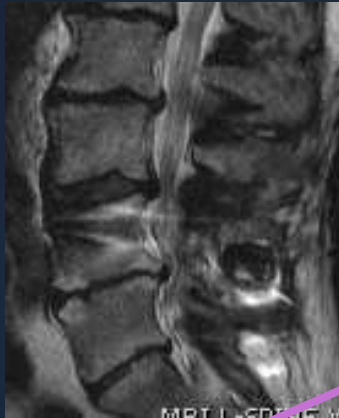



# CASE 6: 46 YO FEMALE, JEHOVAH WITNESS, NEUROGENIC CLAUDICATION, H/O INFX REQUIRED MULTIPLE I&D



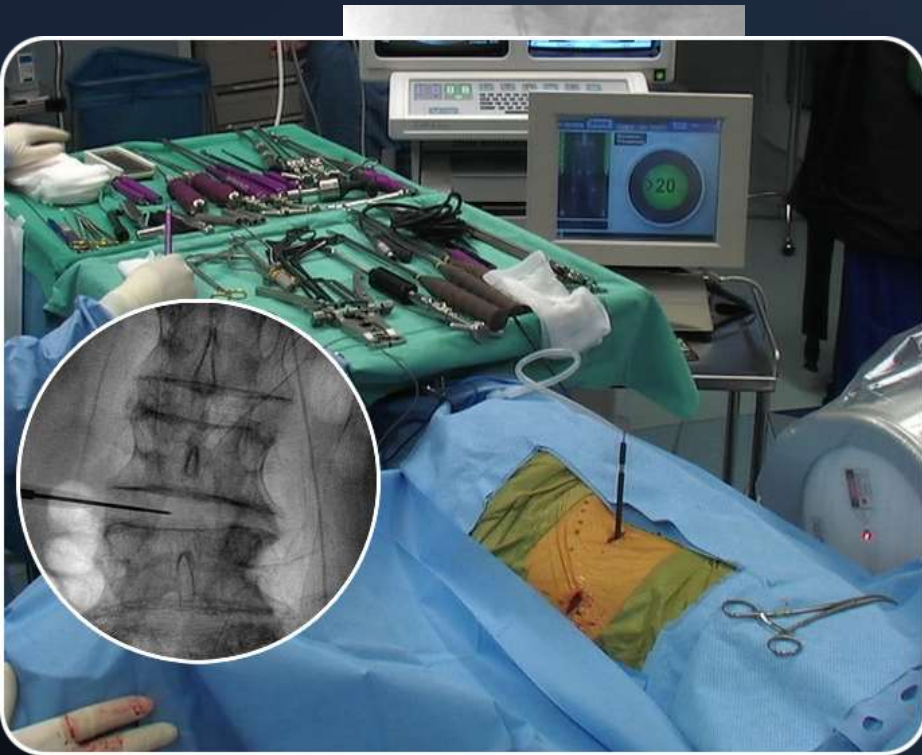
CASE 6: 46 YO FEMALE, JEHOVAH WITNESS,  
NEUROGENIC CLAUDICATION, H/O INFX REQUIRED  
MULTIPLE I&D - *PRE OP MRI*




STENOSIS



CASE 6: 46 YO FEMALE, JEHOVAH WITNESS,  
NEUROGENIC CLAUDICATION, H/O INFX REQUIRED  
MULTIPLE I&D - *INTRA-OP DISC PREPARATION*



CASE 6: 46 YO FEMALE, JEHOVAH WITNESS,  
NEUROGENIC CLAUDICATION, H/O INFX REQUIRED  
MULTIPLE I&D - **ANTERIOR INTERBODY FUSION**

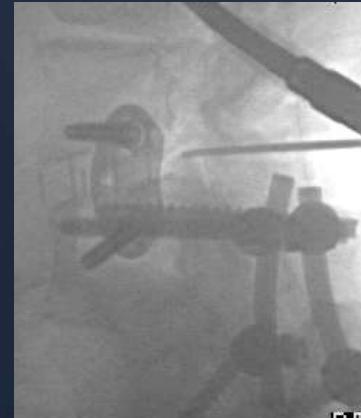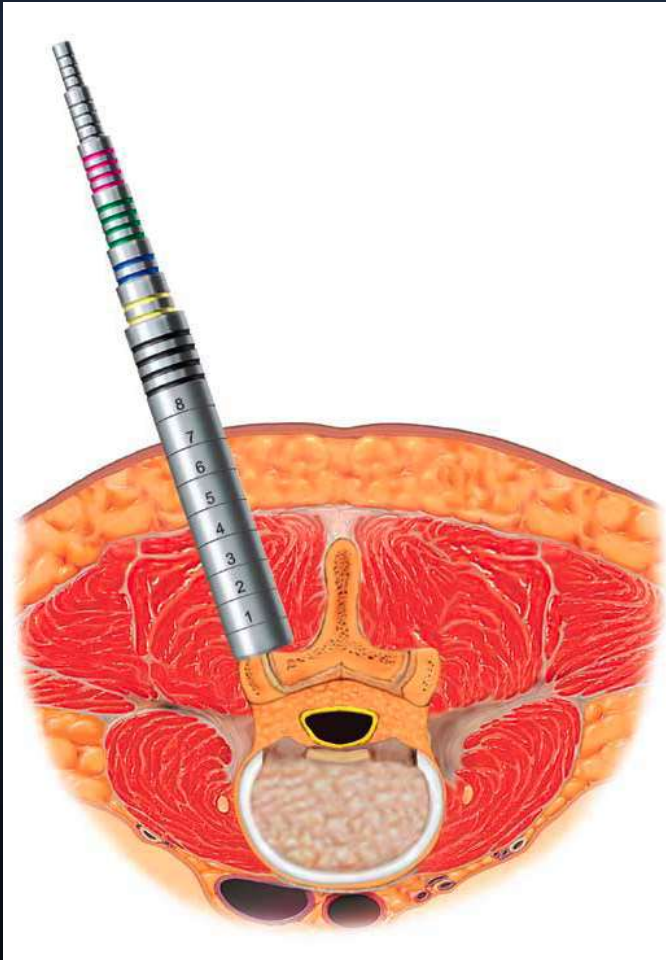


CASE 6: 46 YO FEMALE, JEHOVAH WITNESS,  
NEUROGENIC CLAUDICATION, H/O INFX REQUIRED  
MULTIPLE I&D - **ANTERIOR INSTRUMENTATION**



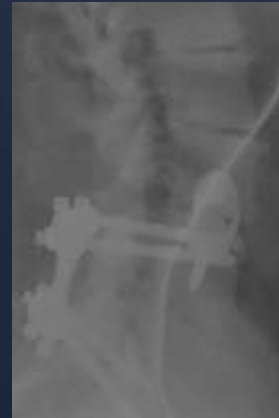
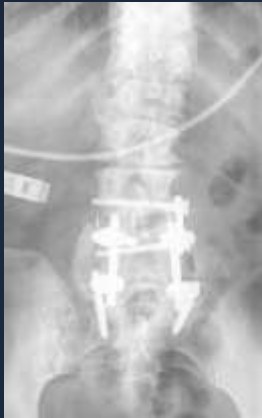
CASE 6: 46 YO FEMALE, JEHOVAH WITNESS,  
NEUROGENIC CLAUDICATION, H/O INFX REQUIRED  
MULTIPLE I&D - **POSTERIOR DECOMPRESSION**

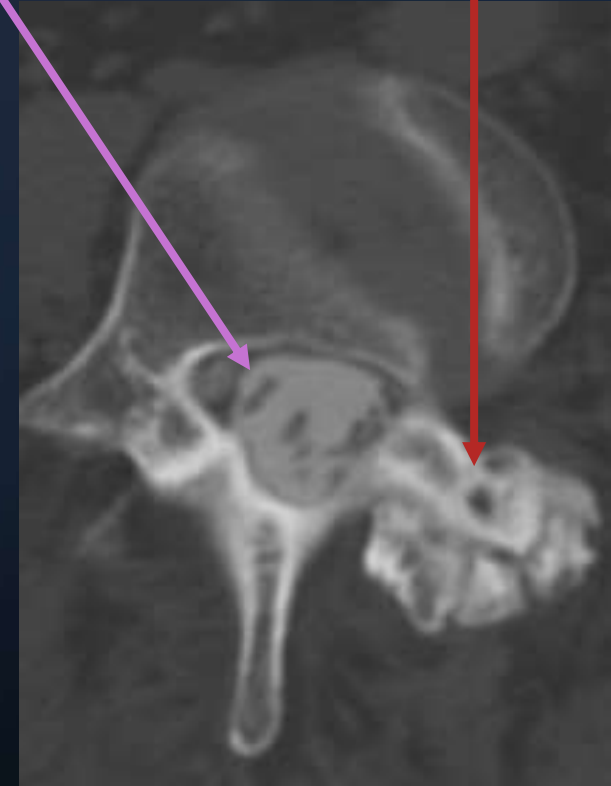
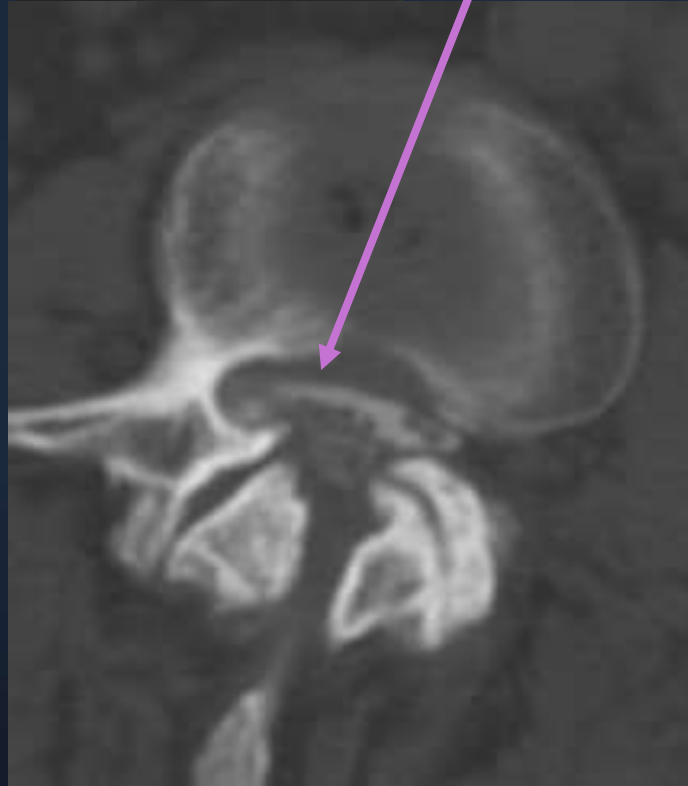
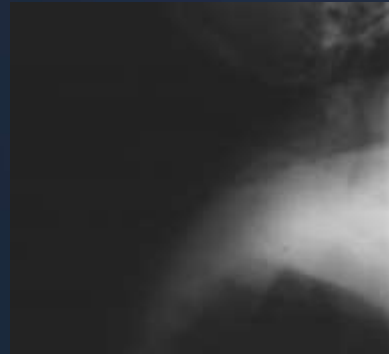
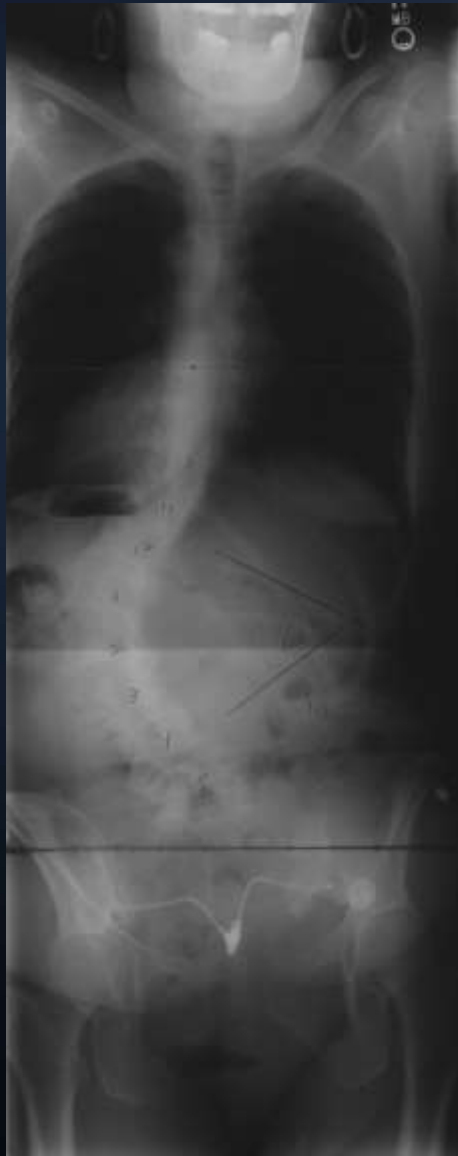
CASE 6: 46 YO FEMALE, JEHOVAH WITNESS,  
NEUROGENIC CLAUDICATION, H/O INFX REQUIRED  
MULTIPLE I&D - POST-OP X-RAY



# CASE 7 : 64 YEAR OLD FEMALE WITH SCOLIOSIS, SPONDYLOLISTHESIS, STENOSIS WITH BACK/LEG PAIN

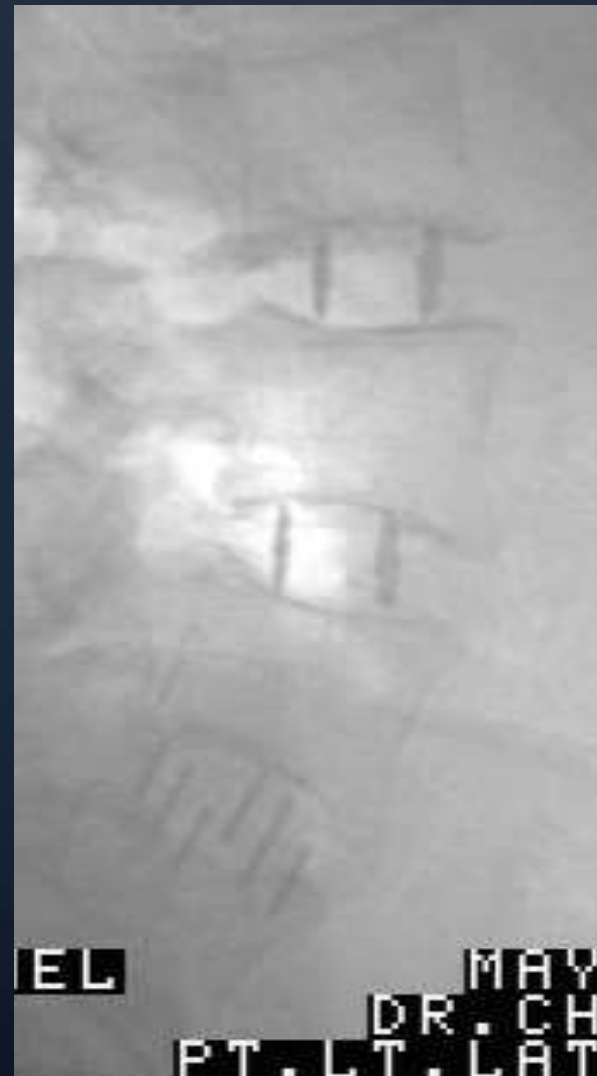

Stenosis

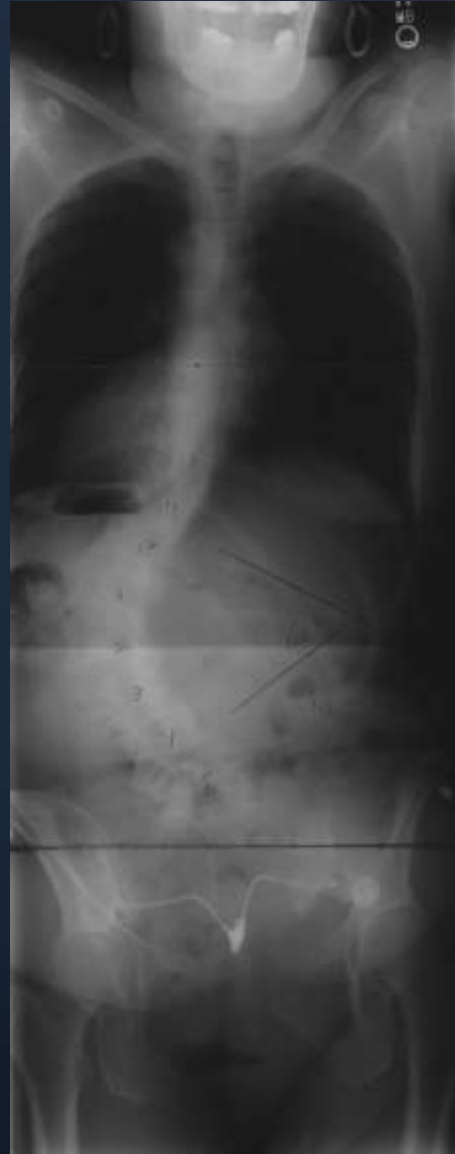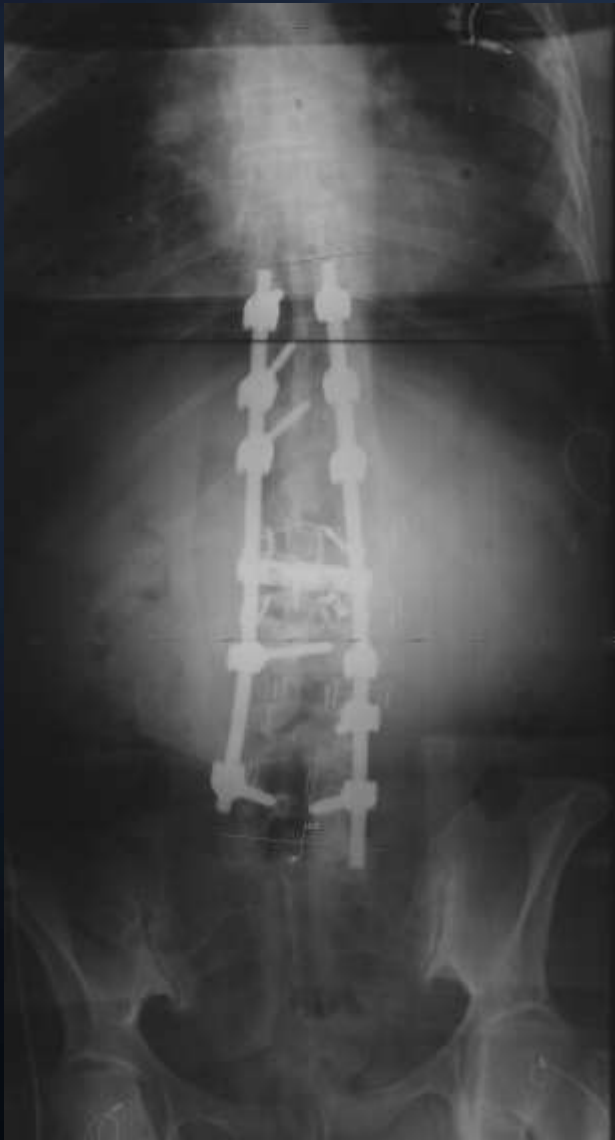Facet arthropathy

Normal Canal

# CASE 6 : 64 YEAR OLD FEMALE WITH SCOLIOSIS, SPONDYLOLISTHESIS, STENOSIS WITH BACK/LEG PAIN



# CASE 6 : 64 YEAR OLD FEMALE WITH SCOLIOSIS, SPONDYLOLISTHESIS, STENOSIS WITH BACK/LEG PAIN



THANK YOU

