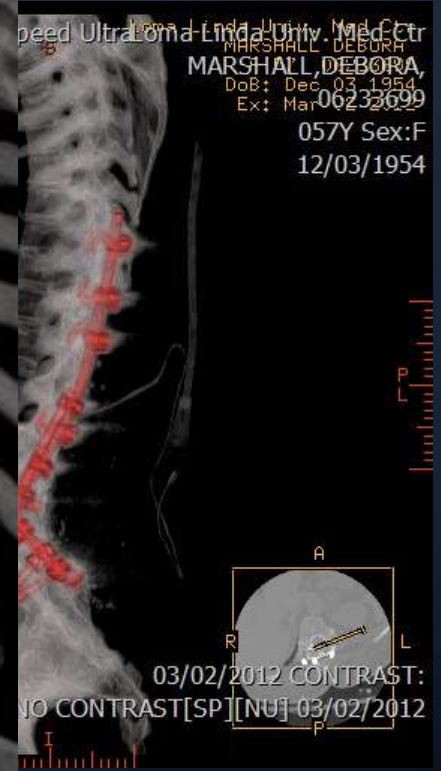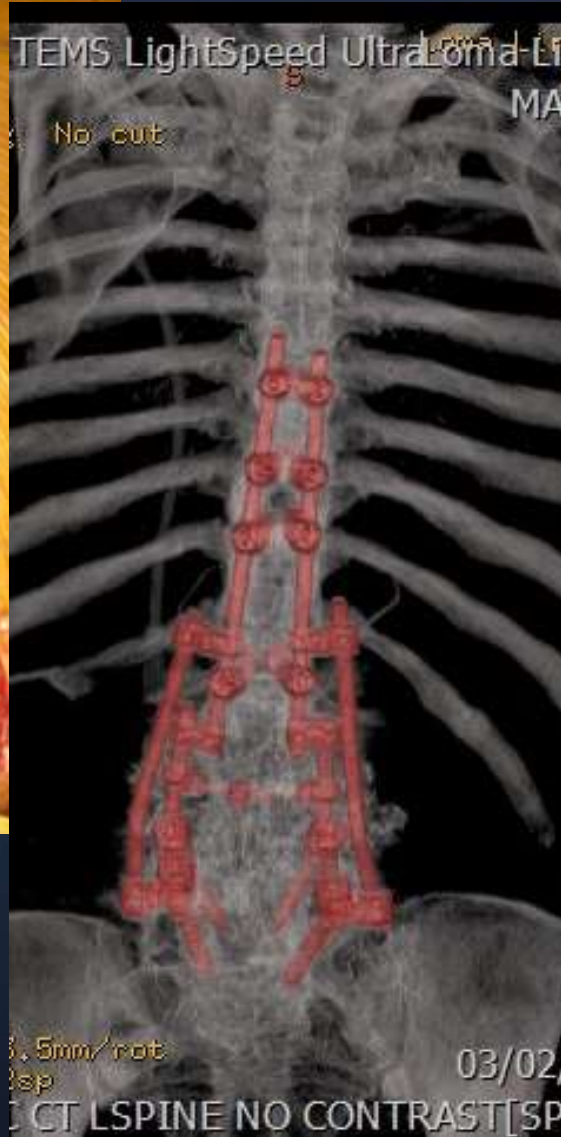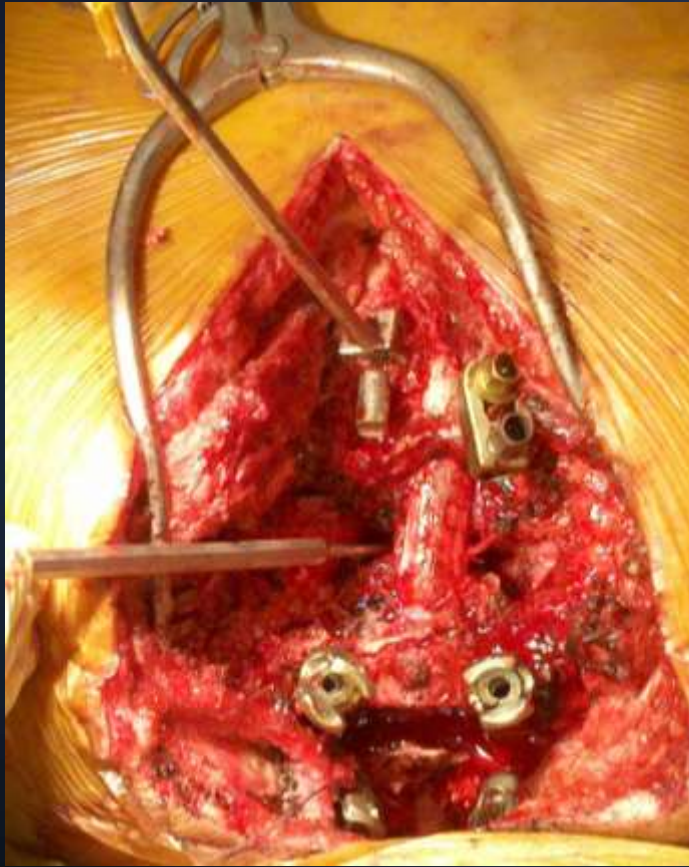




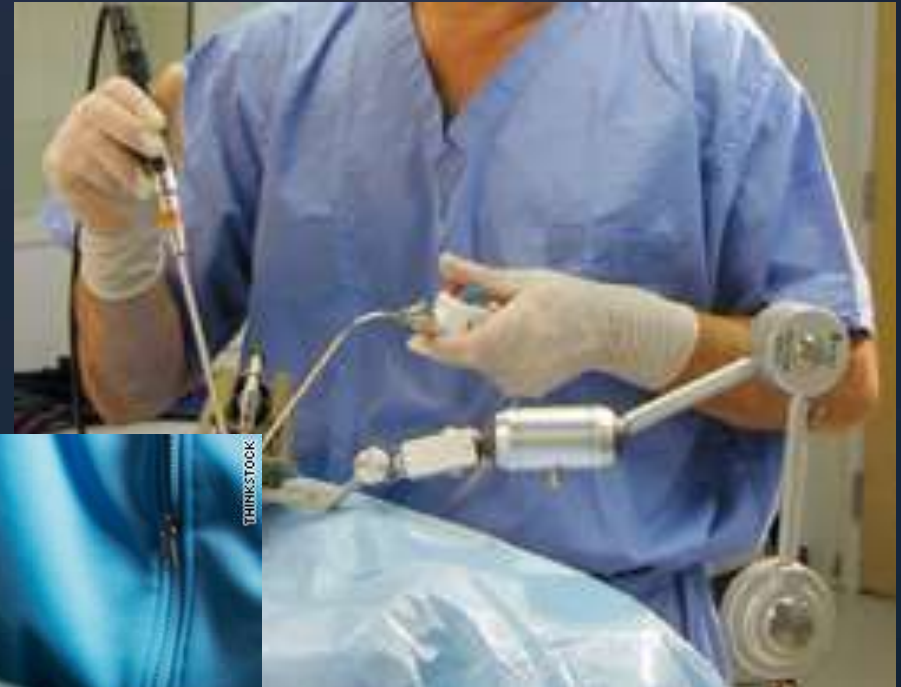# MIS JOURNEY

WAYNE CHENG, MD

*BONES AND SPINE*

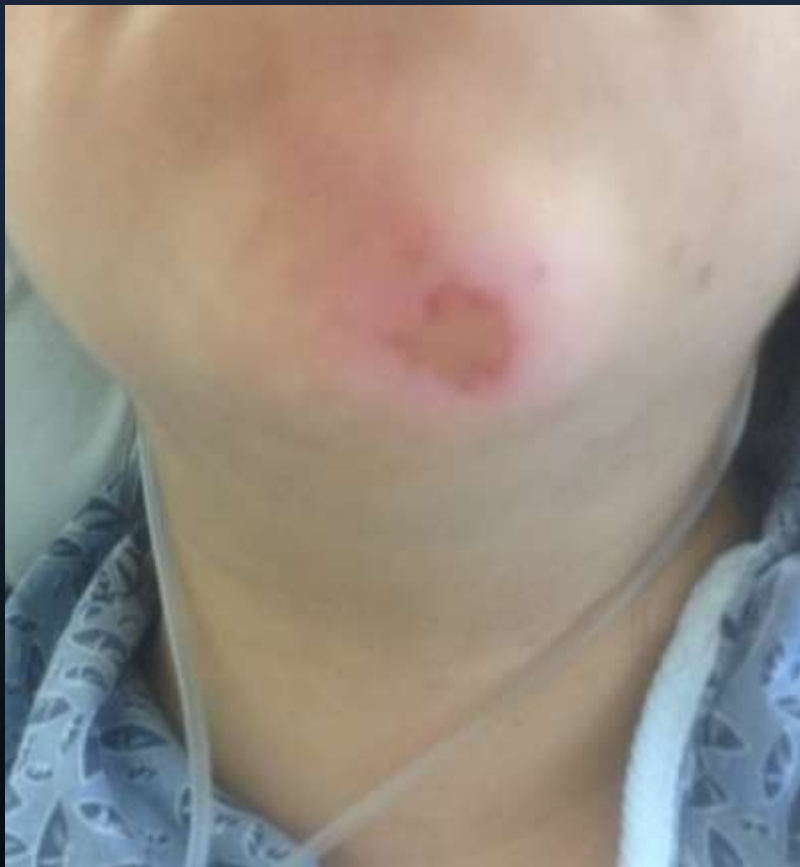

# FIRST ATTEMPT MIS



THINKSTOCK

# TOTAL DISAPPOINTMENT

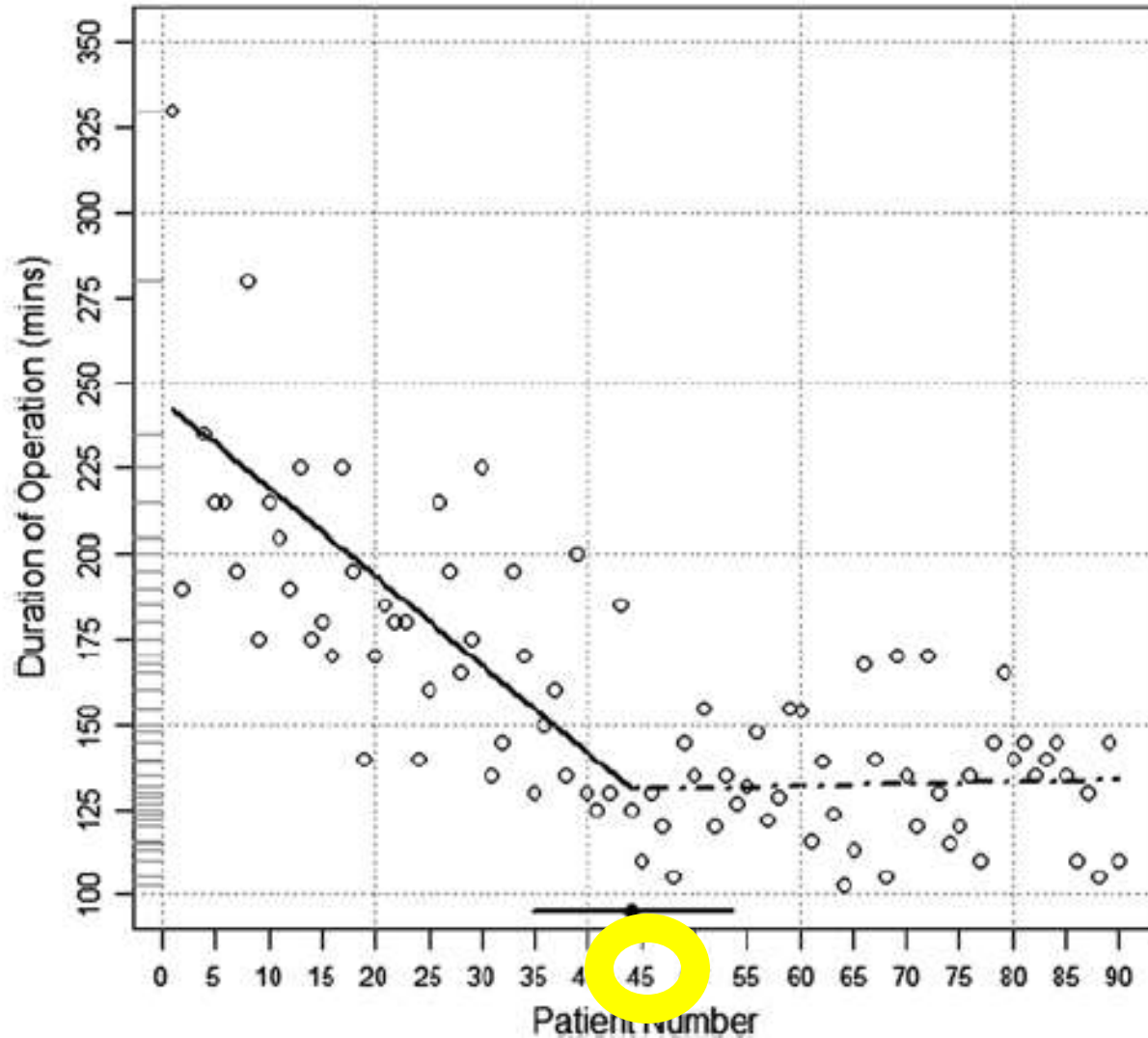


# Learning Curve of a Complex Surgical Technique

## *Minimally Invasive Transforaminal Lumbar Interbody Fusion (MIS TLIF)*

*Kong Hwee Lee, MBBS, MRCSEd, William Yeo, MPhy (Manips),*

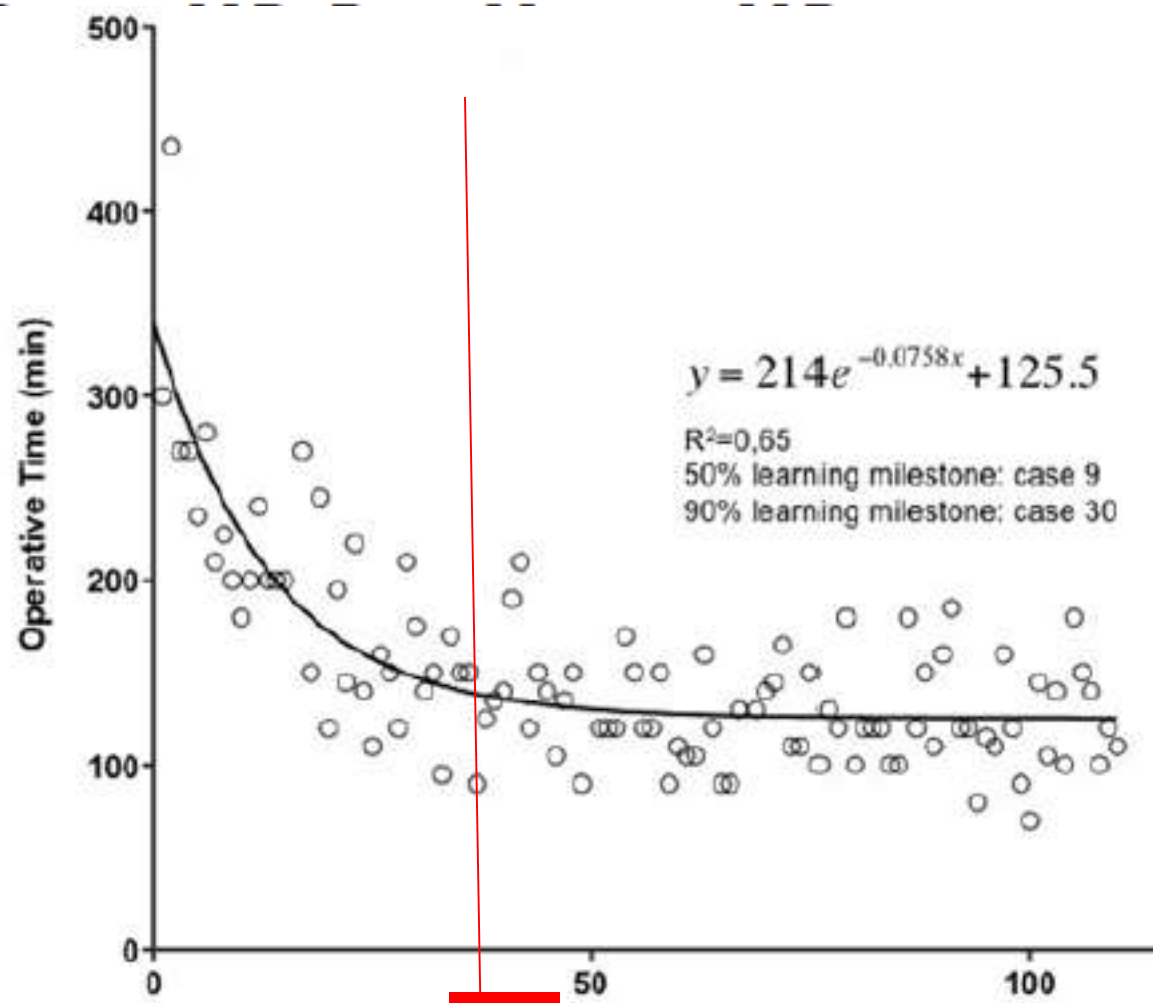
*Henry Soeharno, MBBS, MRCSEd, and Wai Mun Yue, MBBS, FRCSEd, FAMS (Ortho Surgery)*





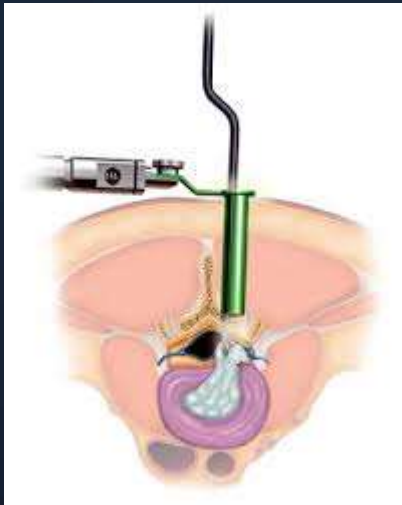
# Learning curve and complications of minimally invasive transforaminal lumbar interbody fusion

\*PEDRO S. SILVA, M.D., PAULO PEDRO A. SILVA, M.D., AND RU



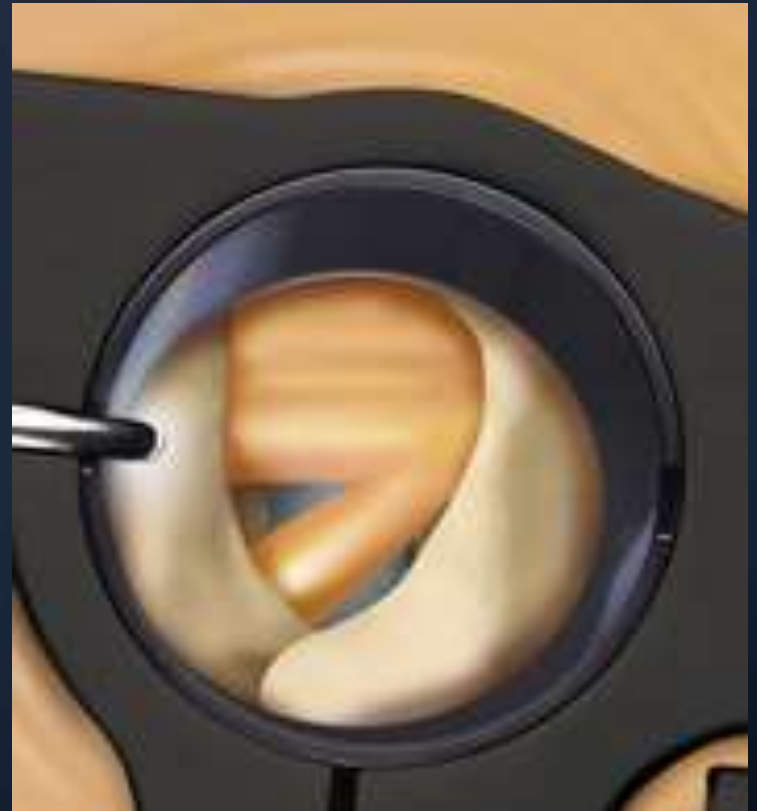
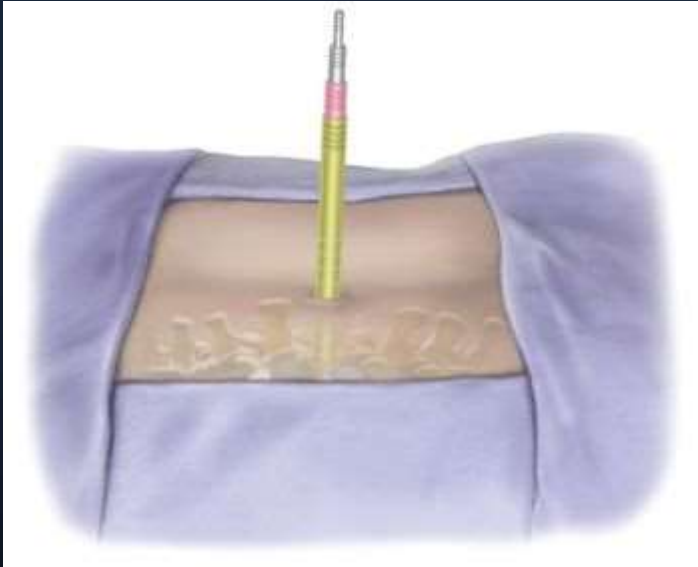- “Spine surgery is like having sex, why would you want to do it minimally invasive?”

# TUBULAR RETRACTOR

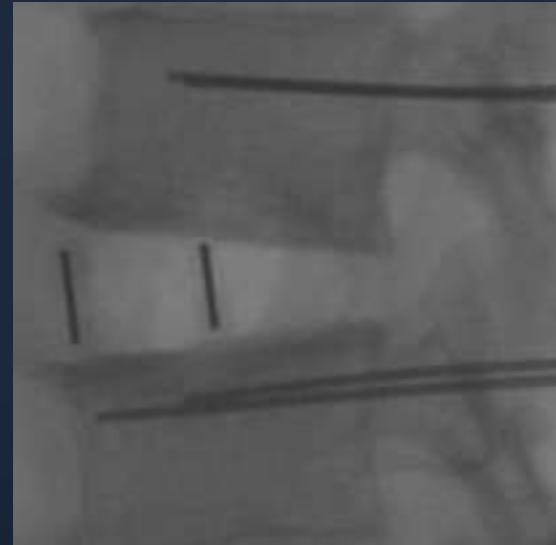
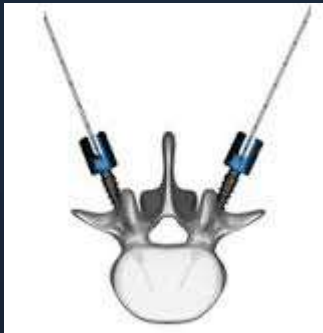


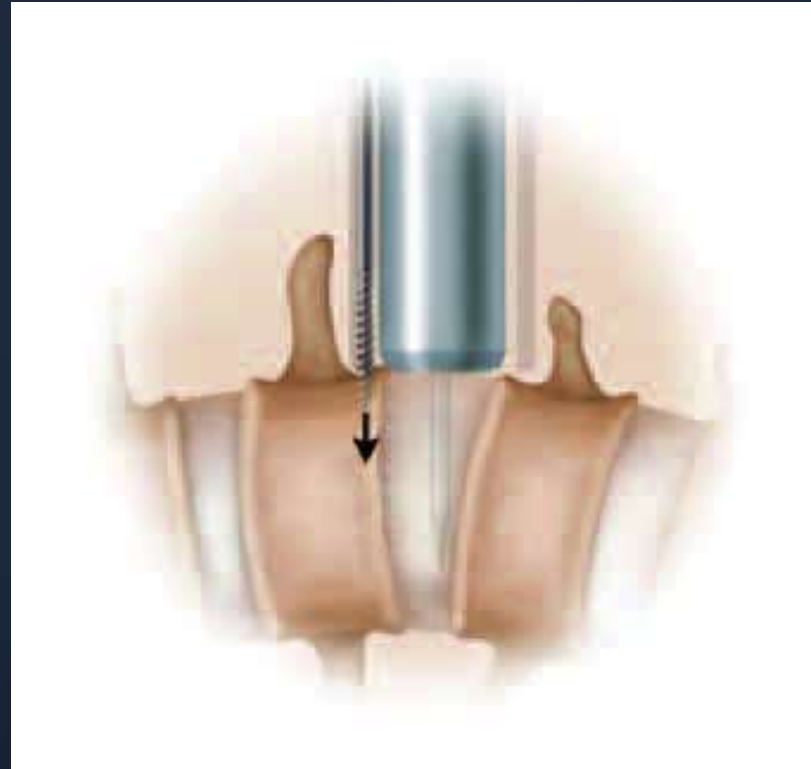
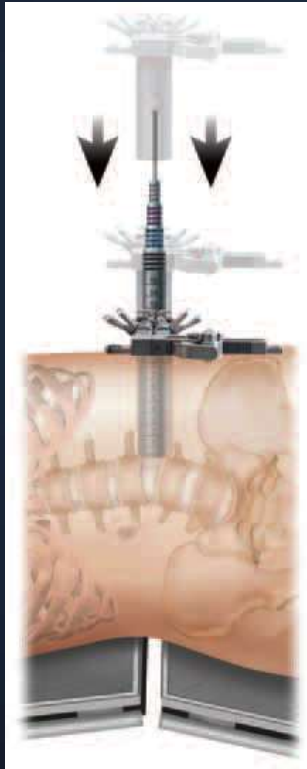
# MICROSCOPIC ANATOMY



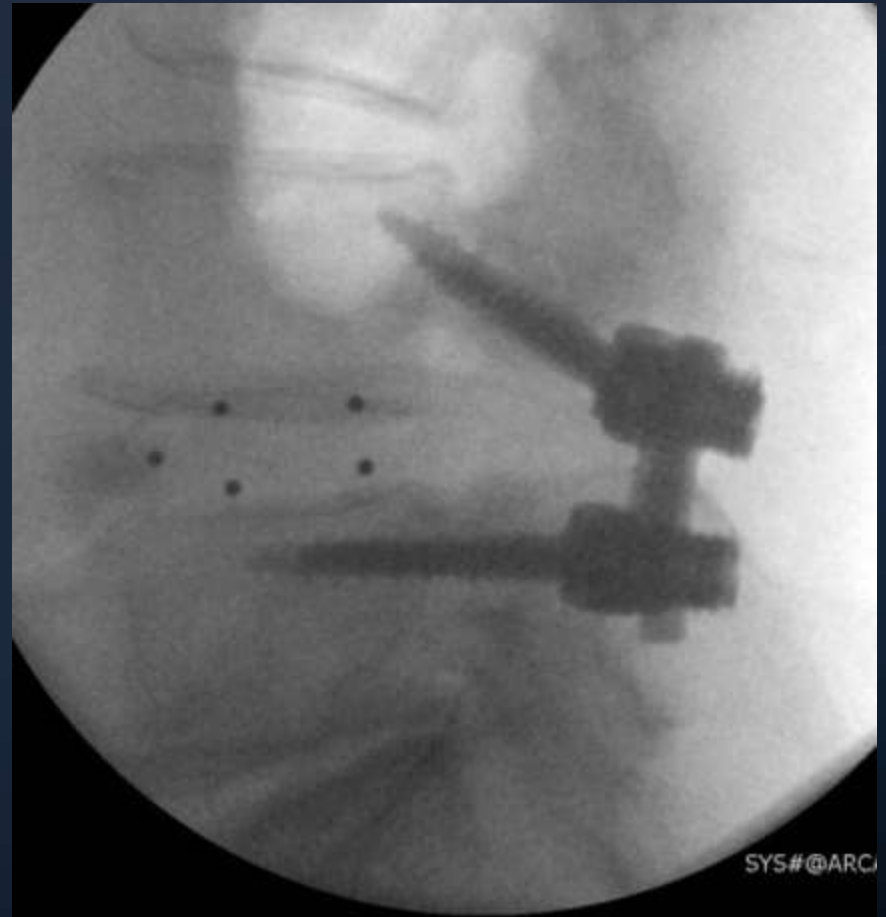
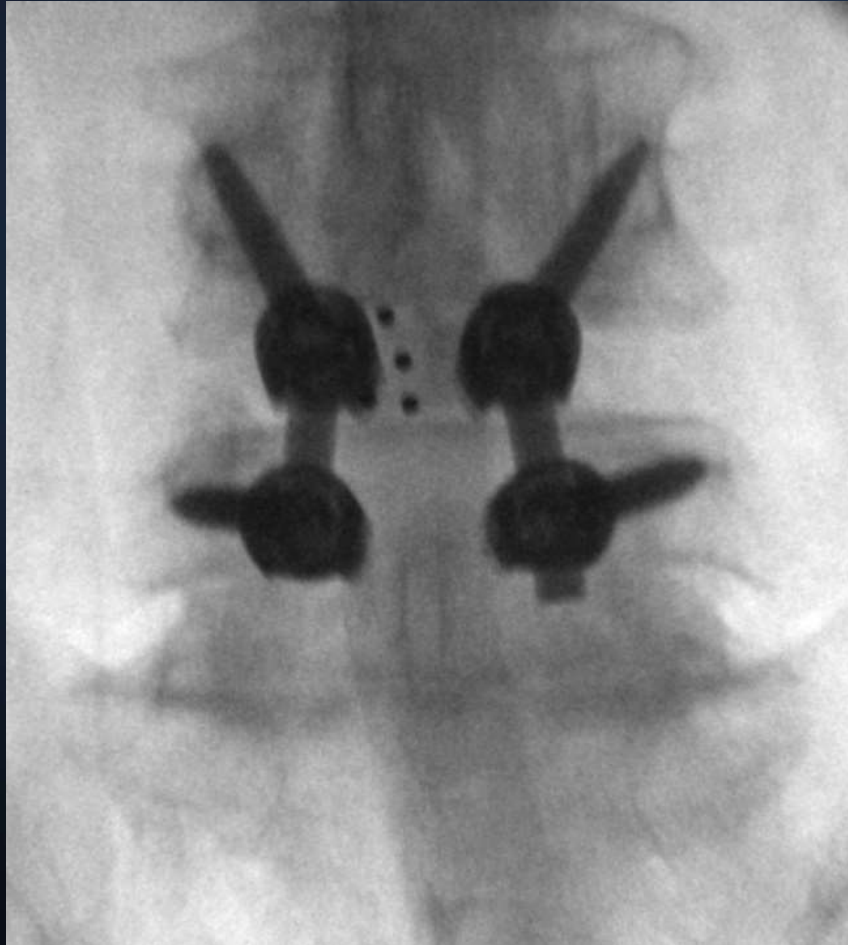
# PERCUTANEOUS SCREWS



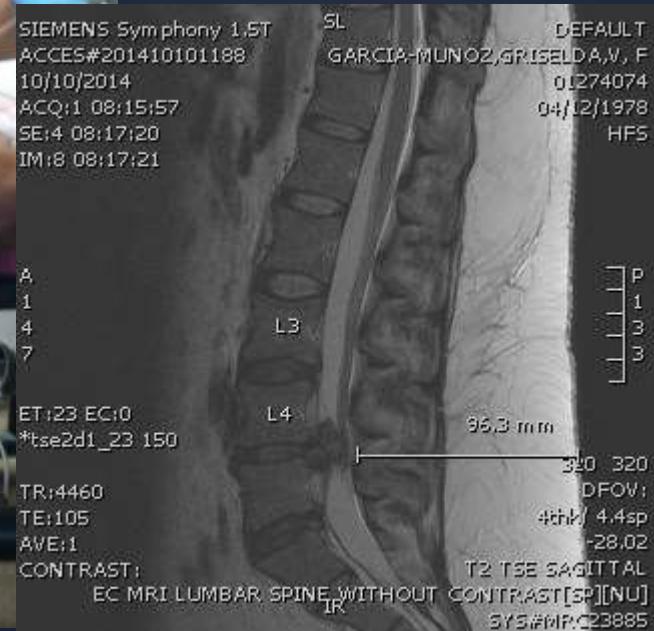
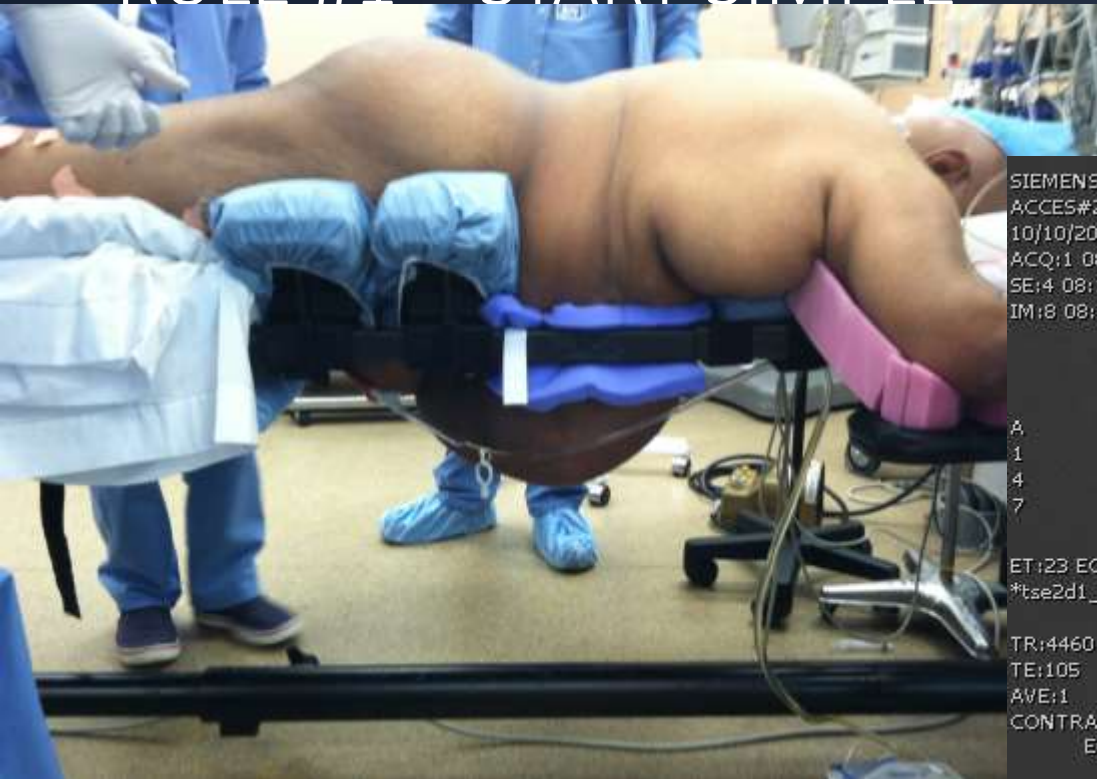# TRANSPOAS INTERBODY FUSION

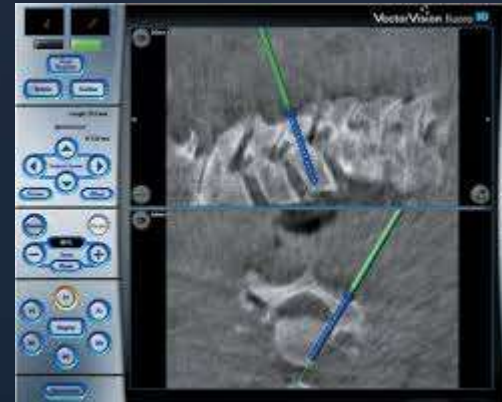
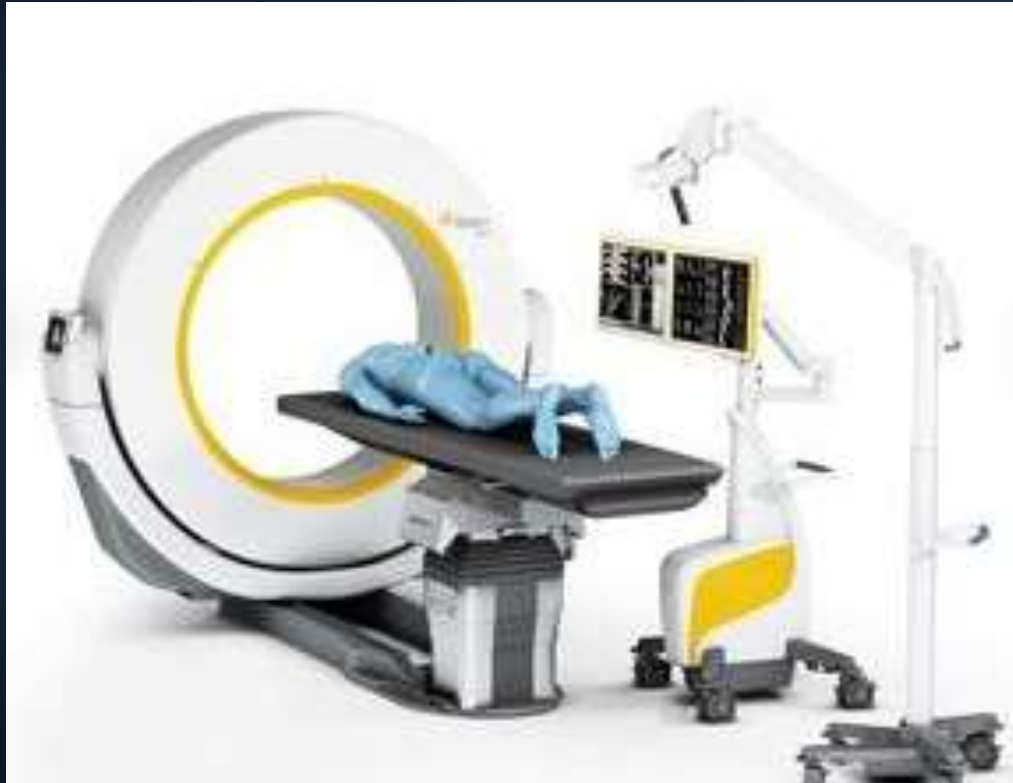
# CORTICAL SCREW TRAJECTORY

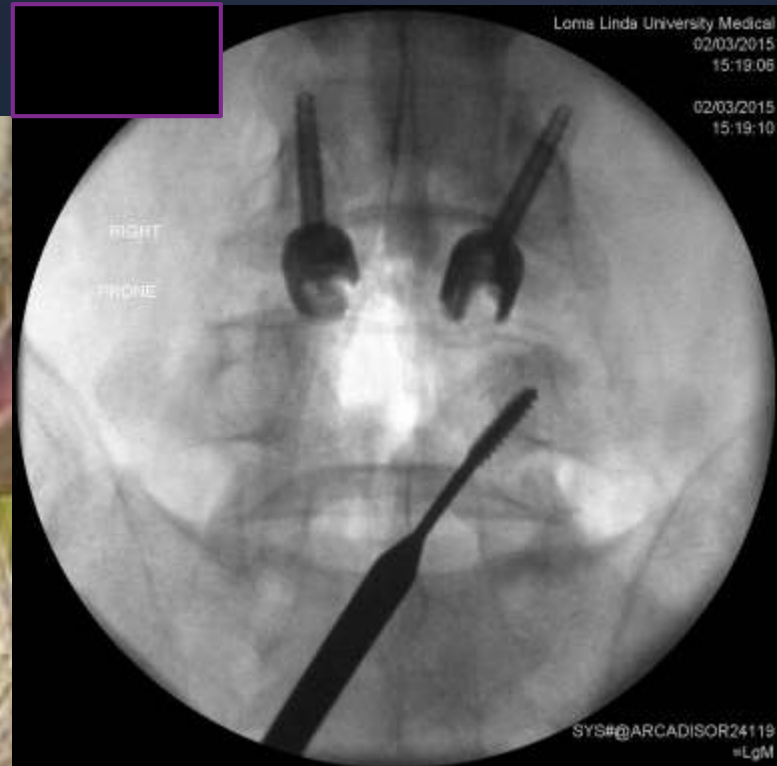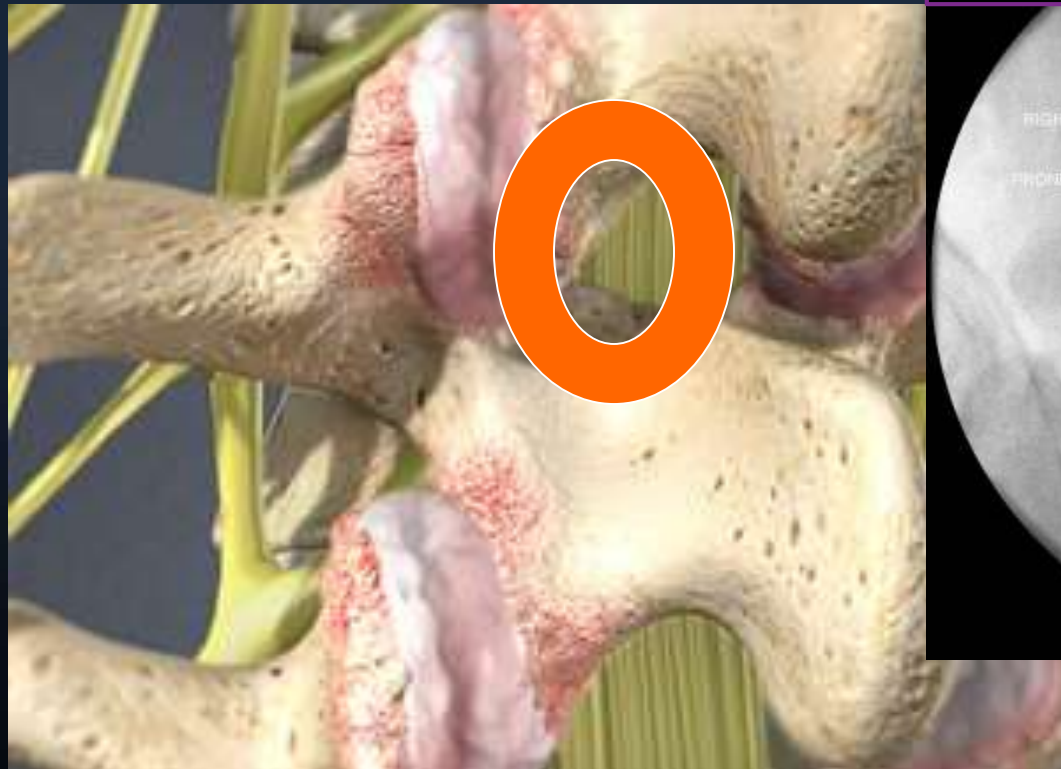


# RULE #1 – START SIMPLE





# RULE #2 – BE CONSISTENT LOOK FOR THE SAME LANDMARK

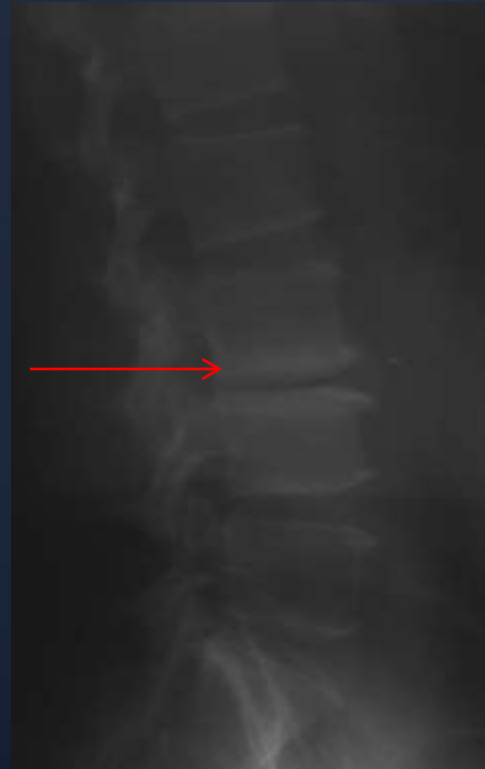
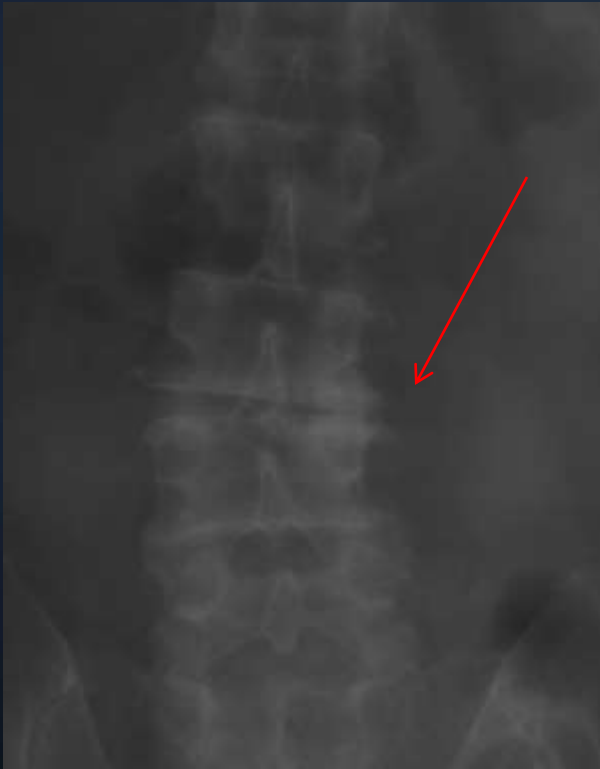
## RULE #3 – GET A MENTOR

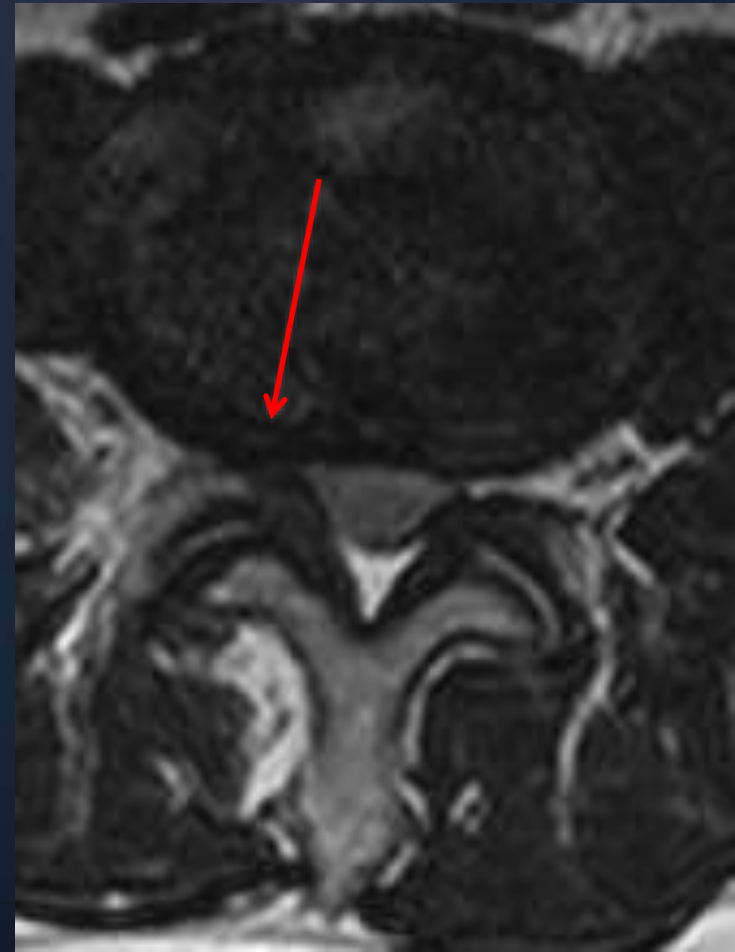
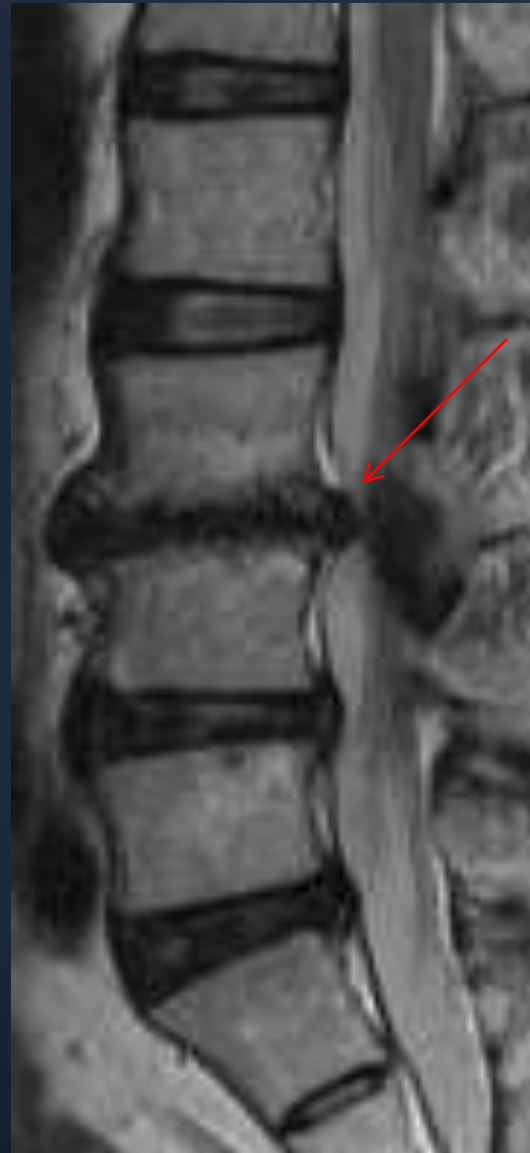
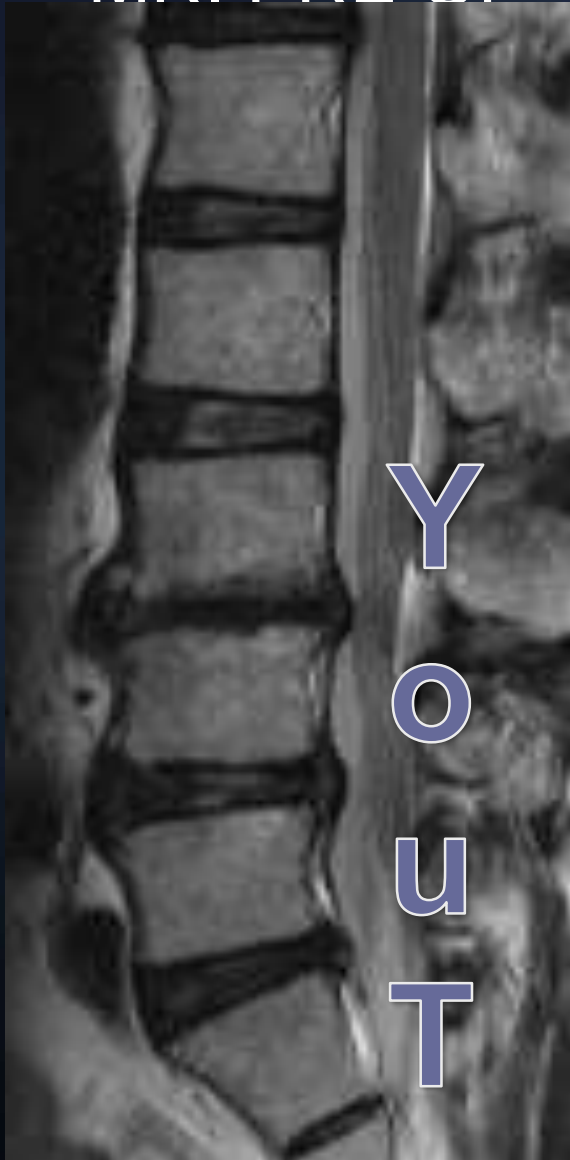



CASE 65 yo with lower back pain and right thigh pain

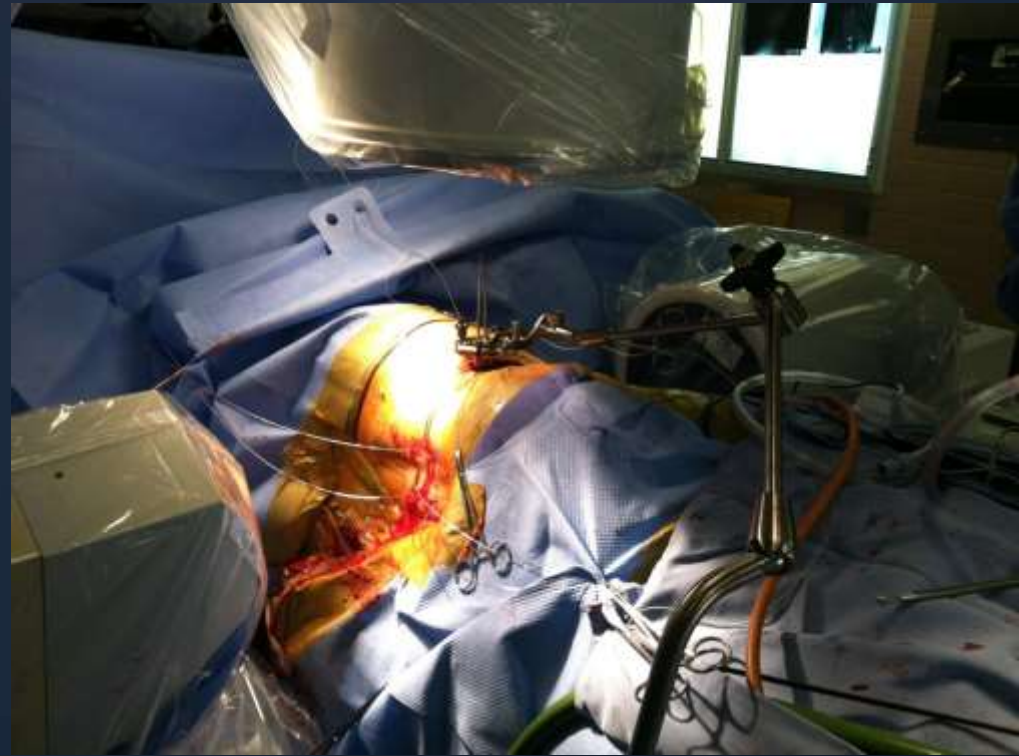
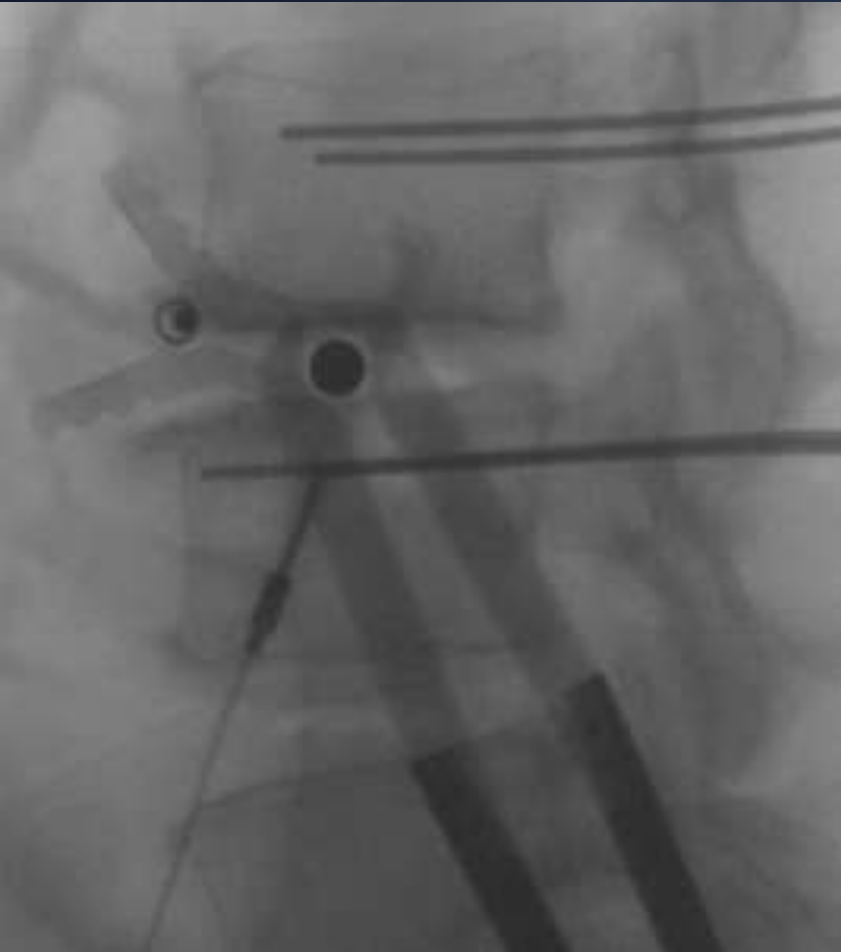
# MRI PRE OP

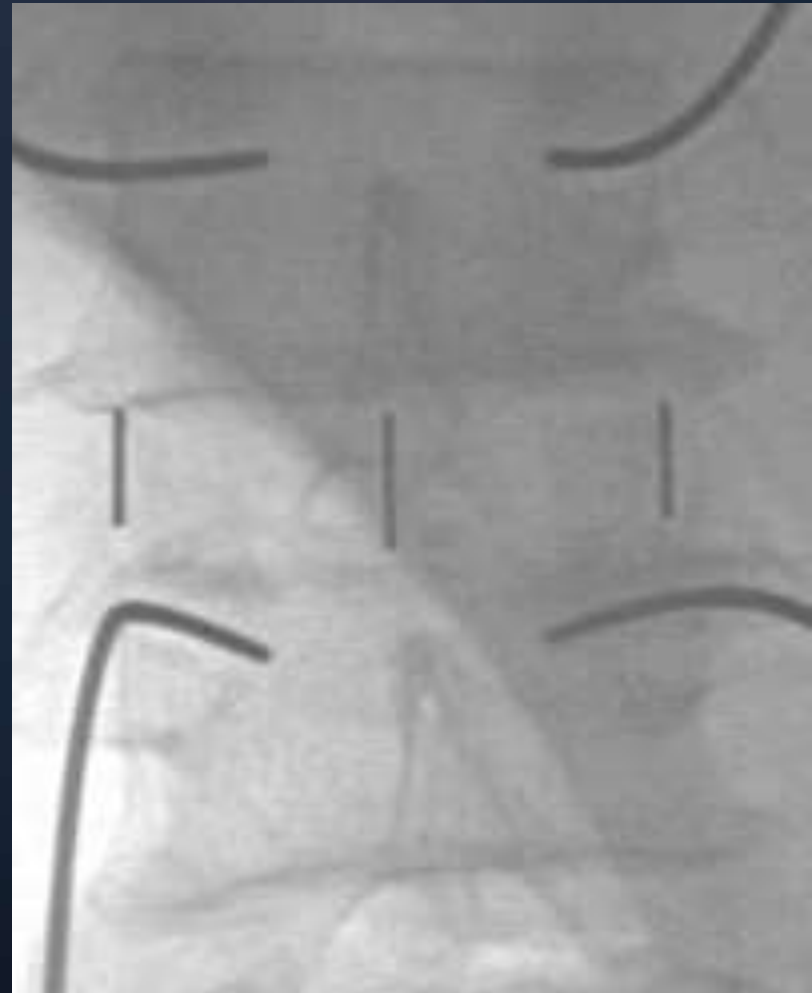
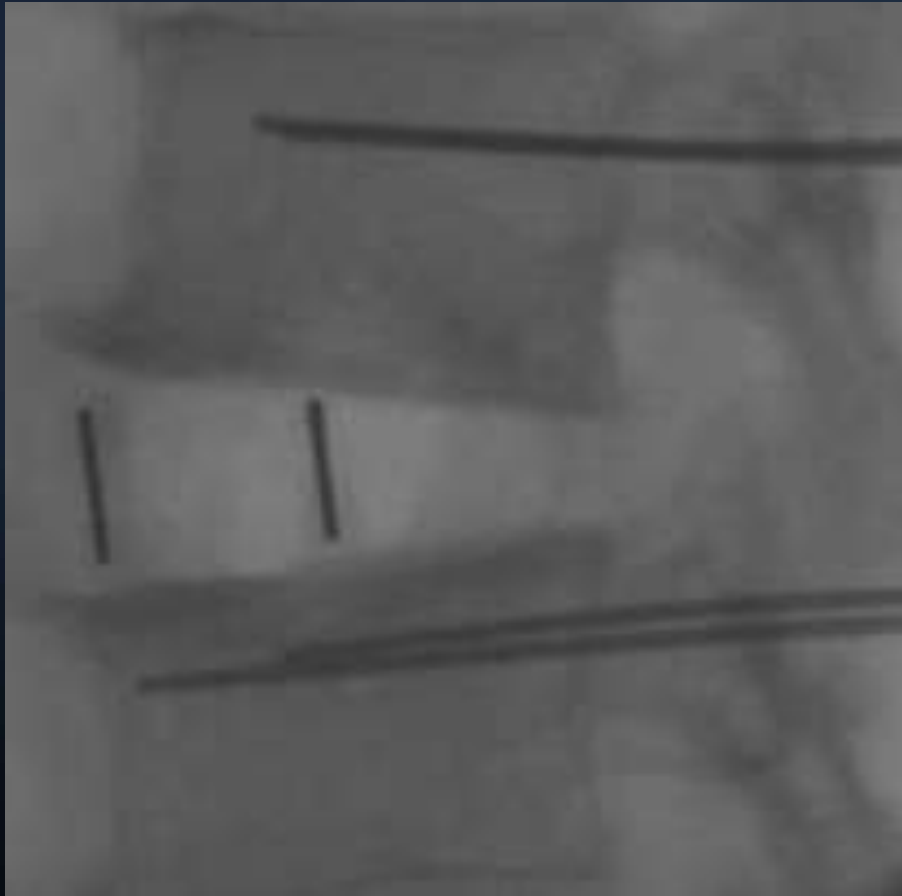
e

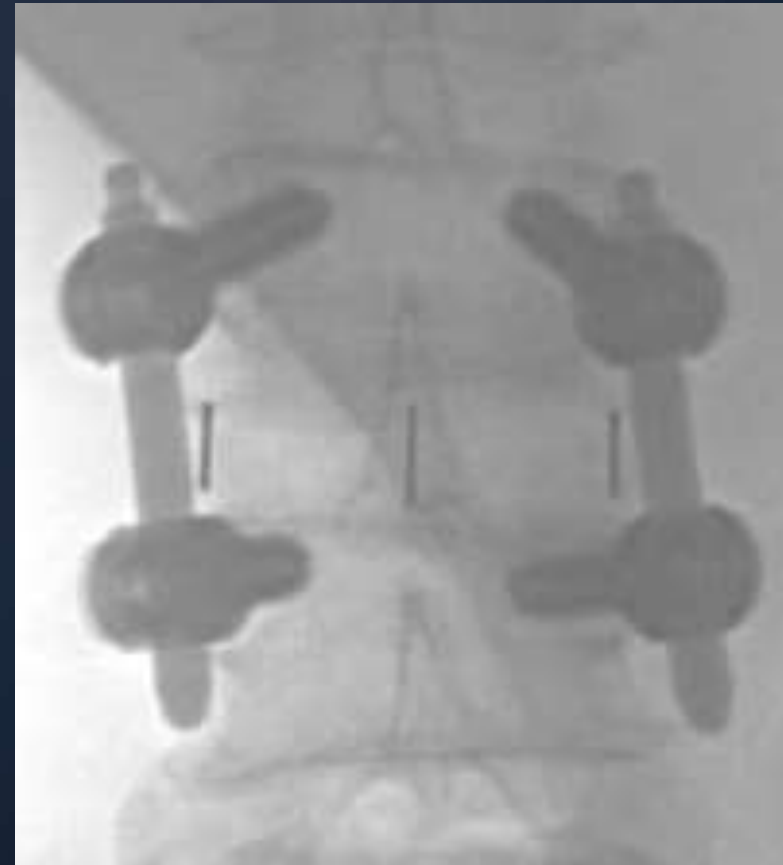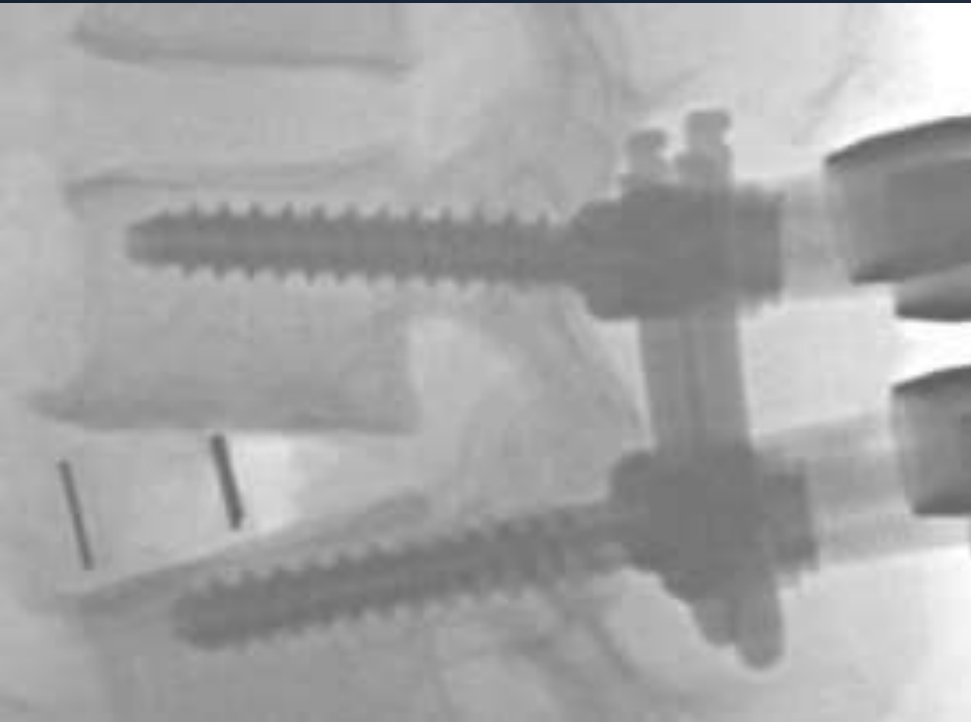# CASE 1 - INTRA OP



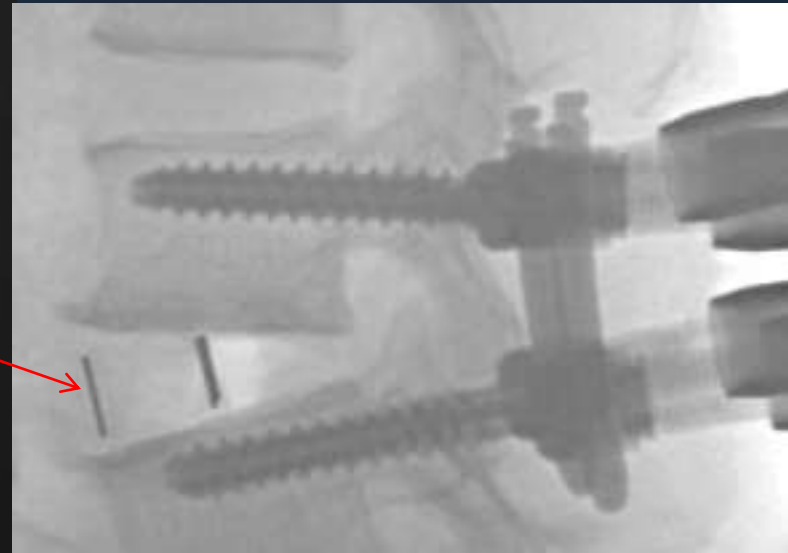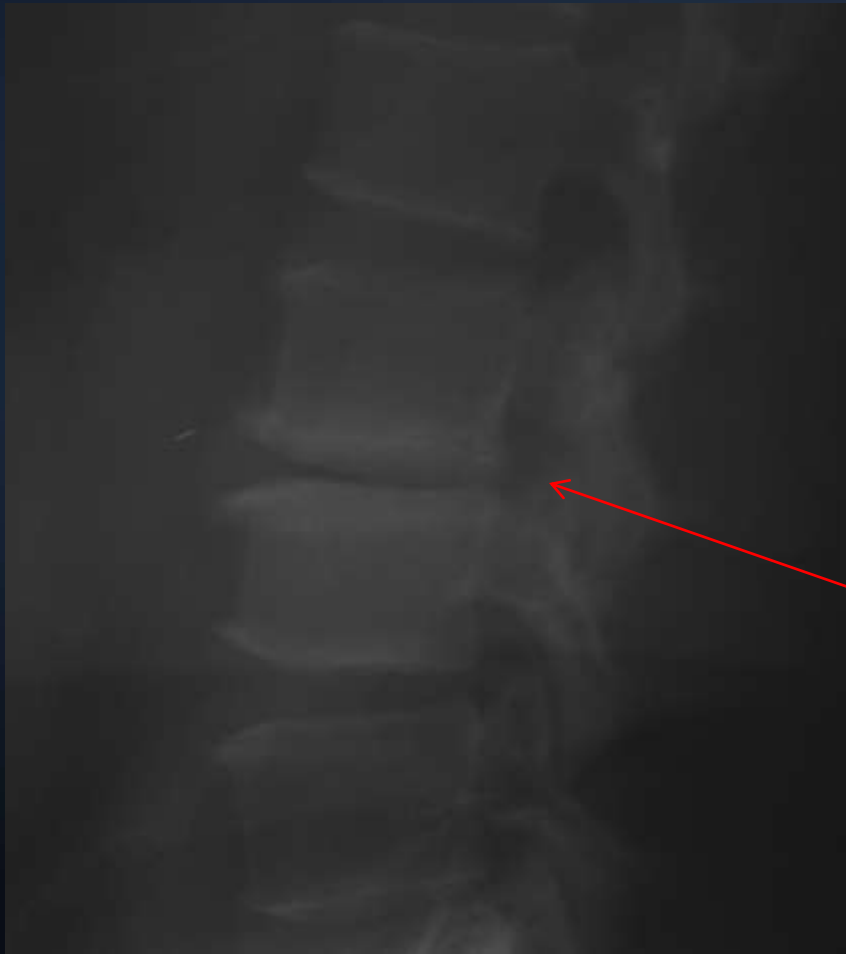# CASE 1- INTRA OP



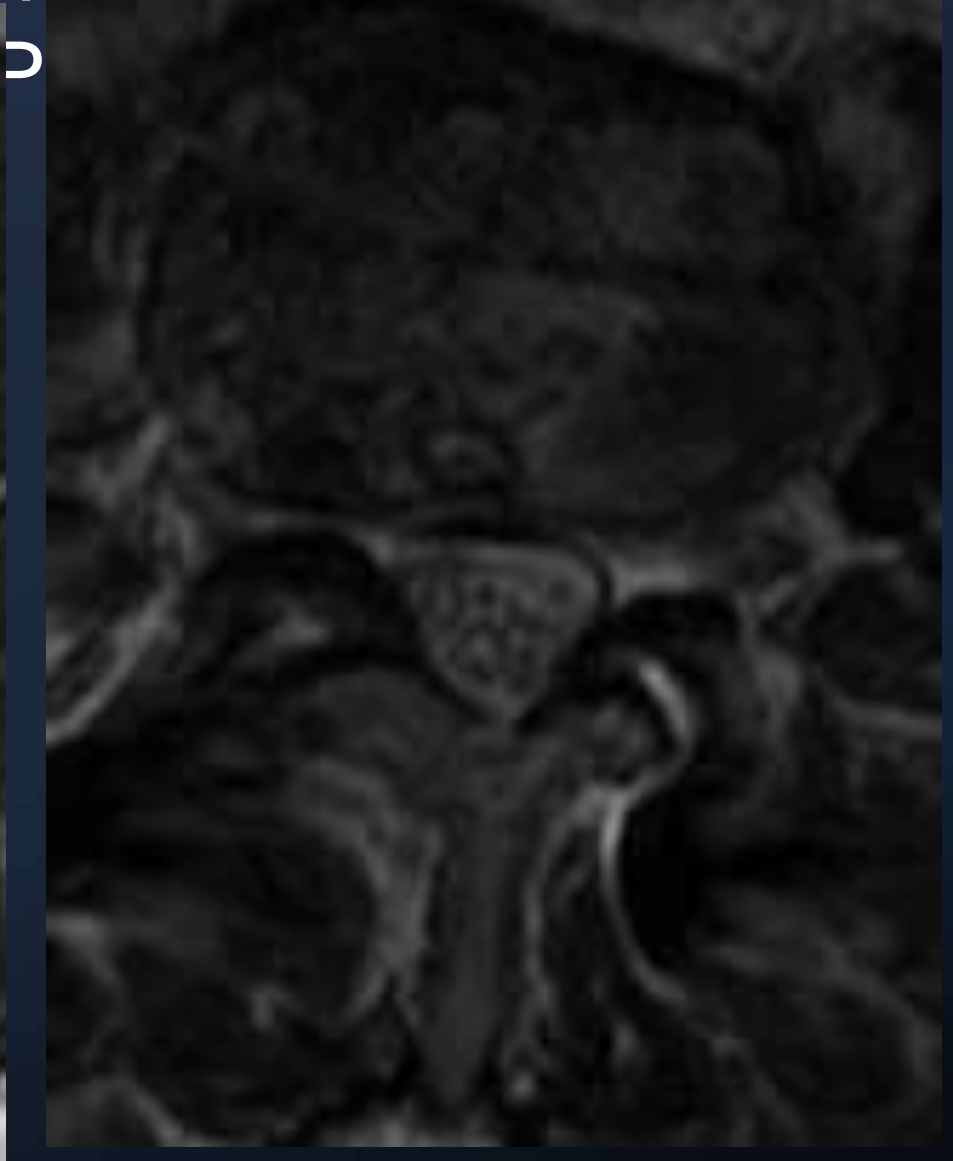
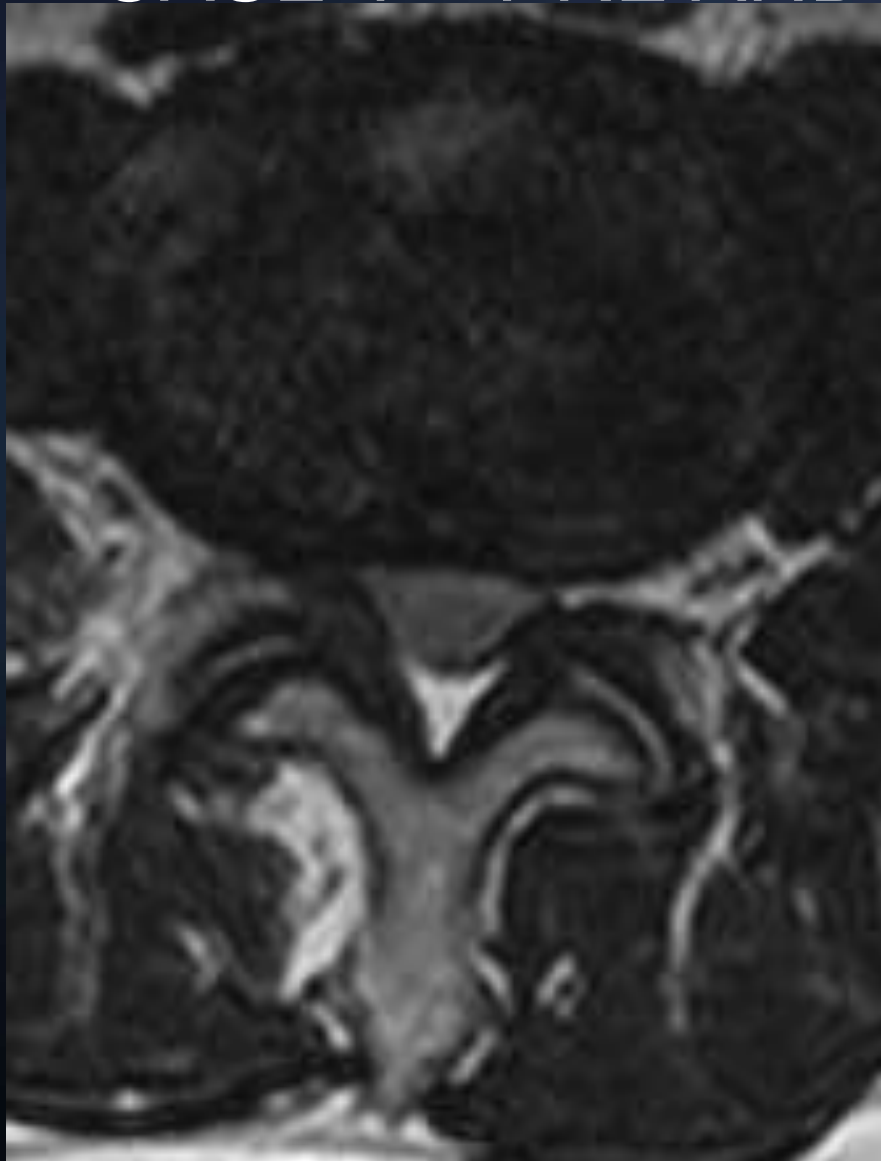
# CASE 1 INTRA OP



# CASE 1 – PRE AND POST OP XRAY

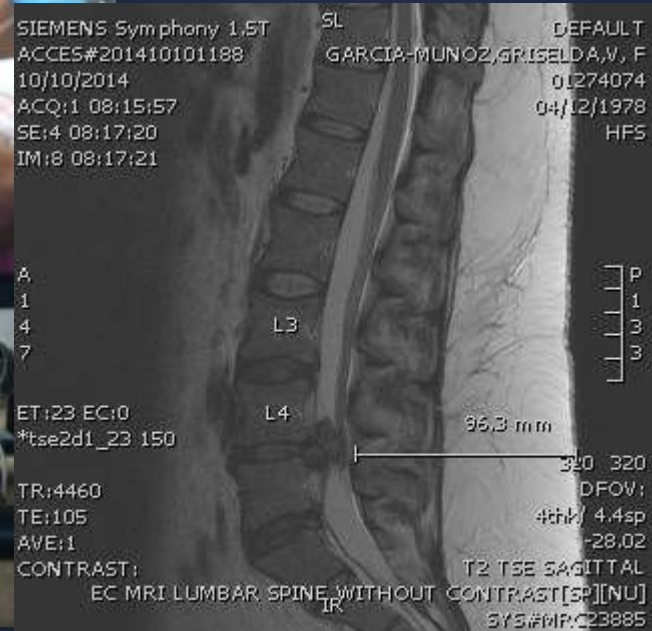
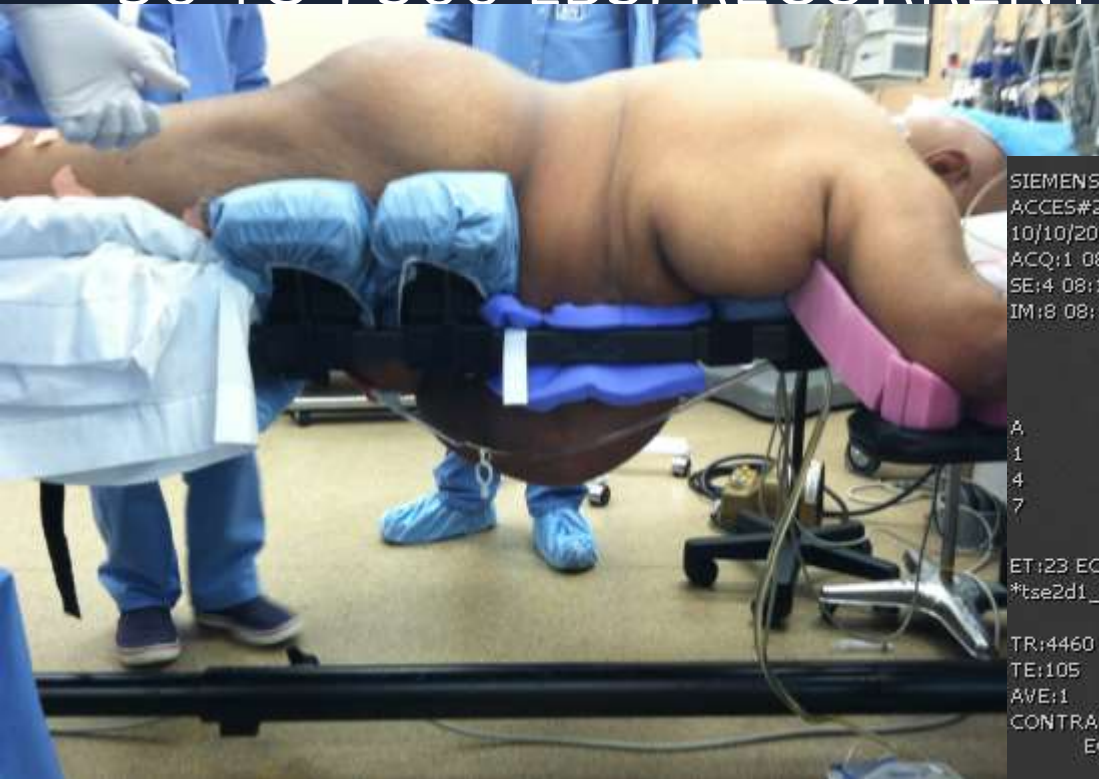

# CASE 1 – PRE AND POST OP MRI



# CASE 2

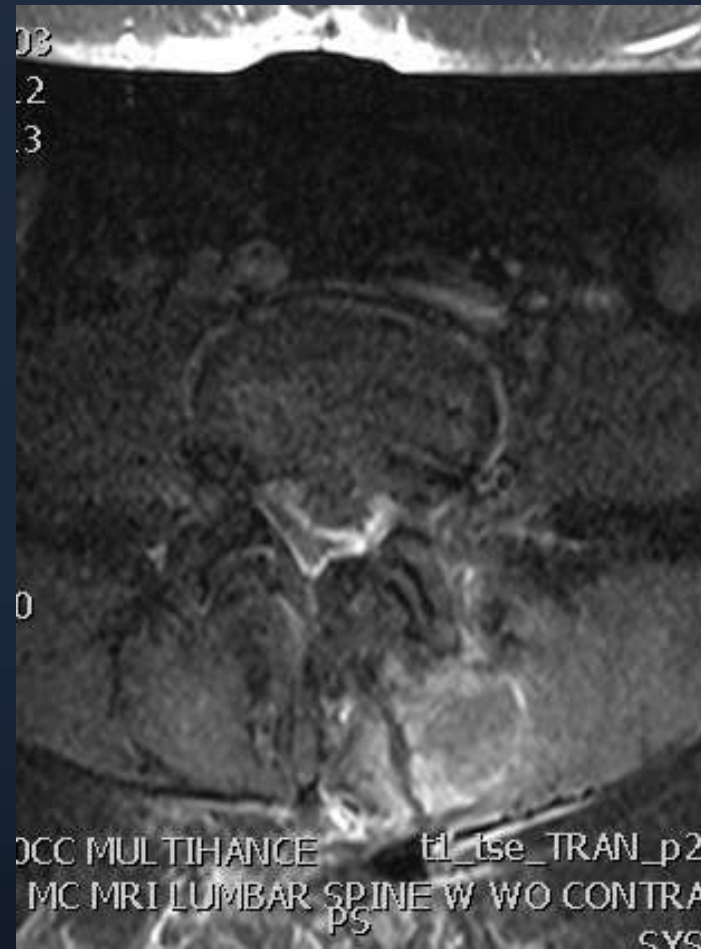
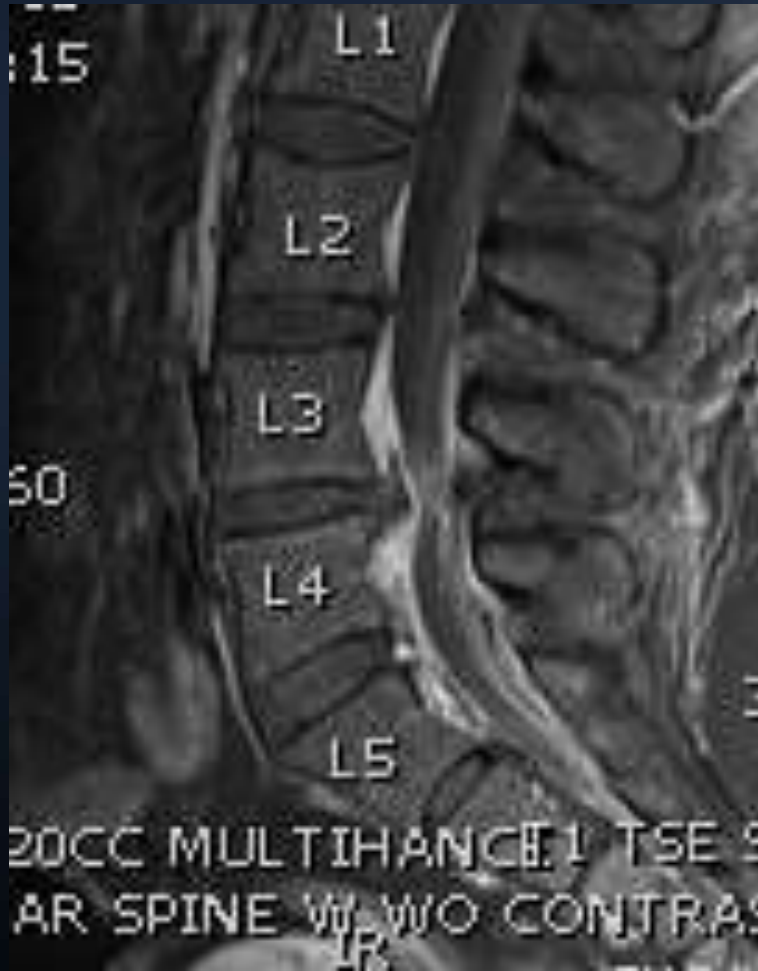## 56 YO, 300 LBS, RECURRENT HNP



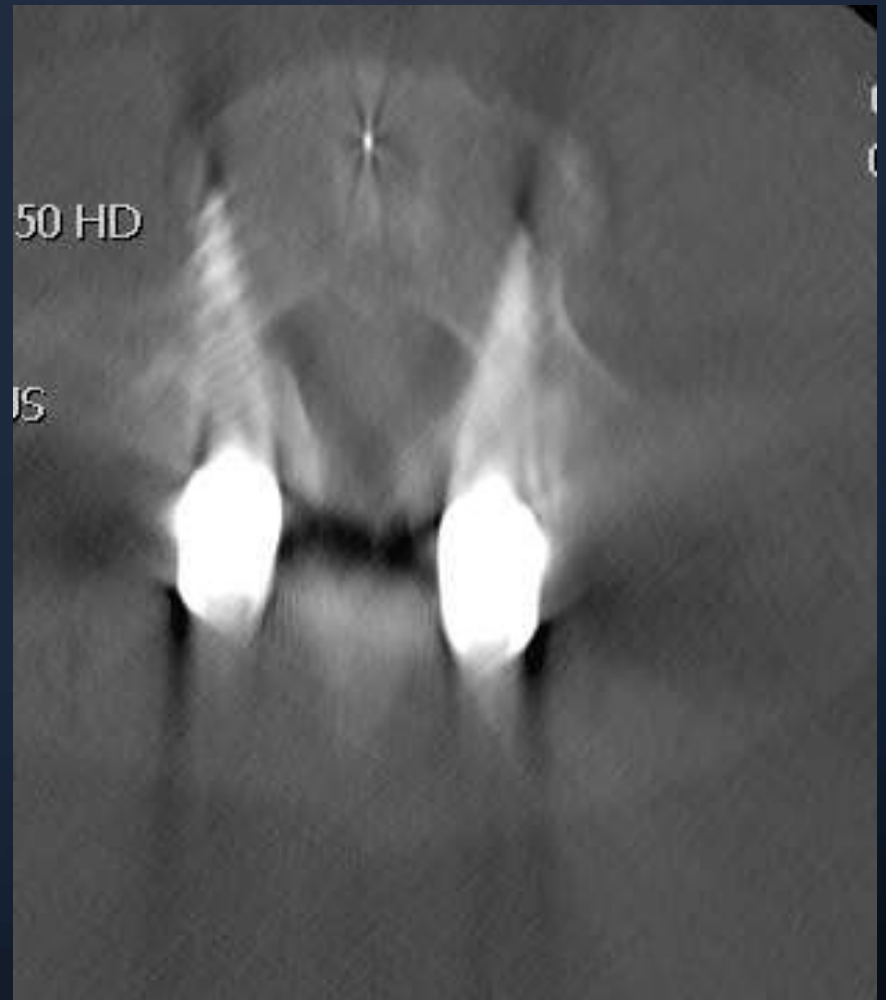
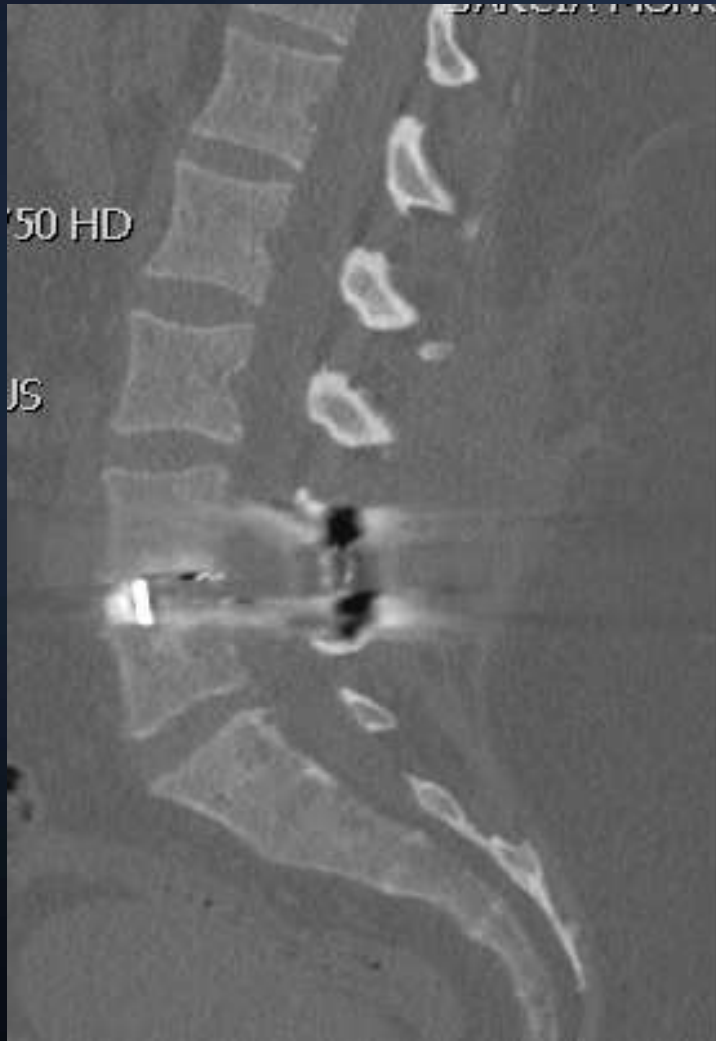
# CASE 2

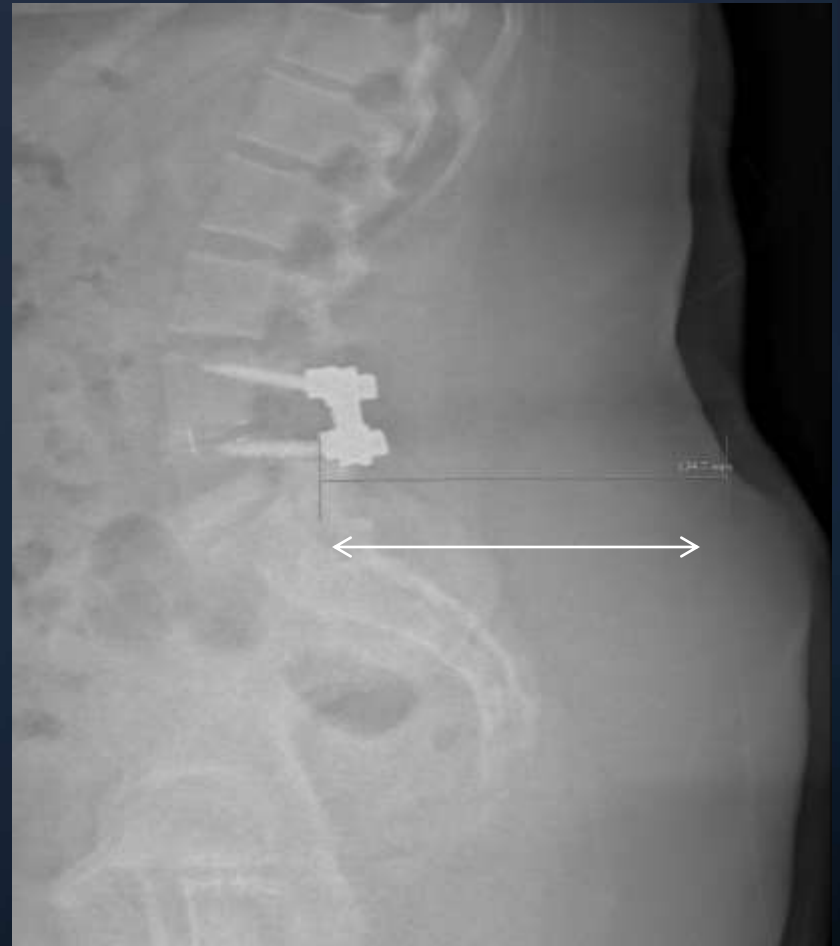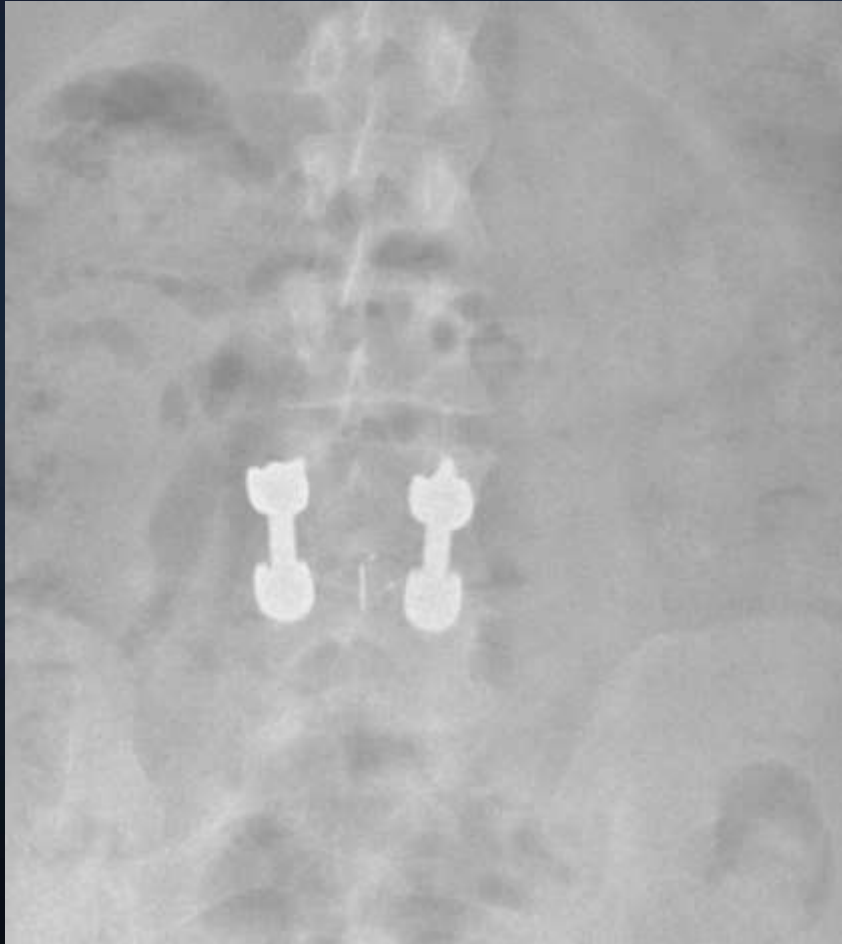
## RECURRENT HNP



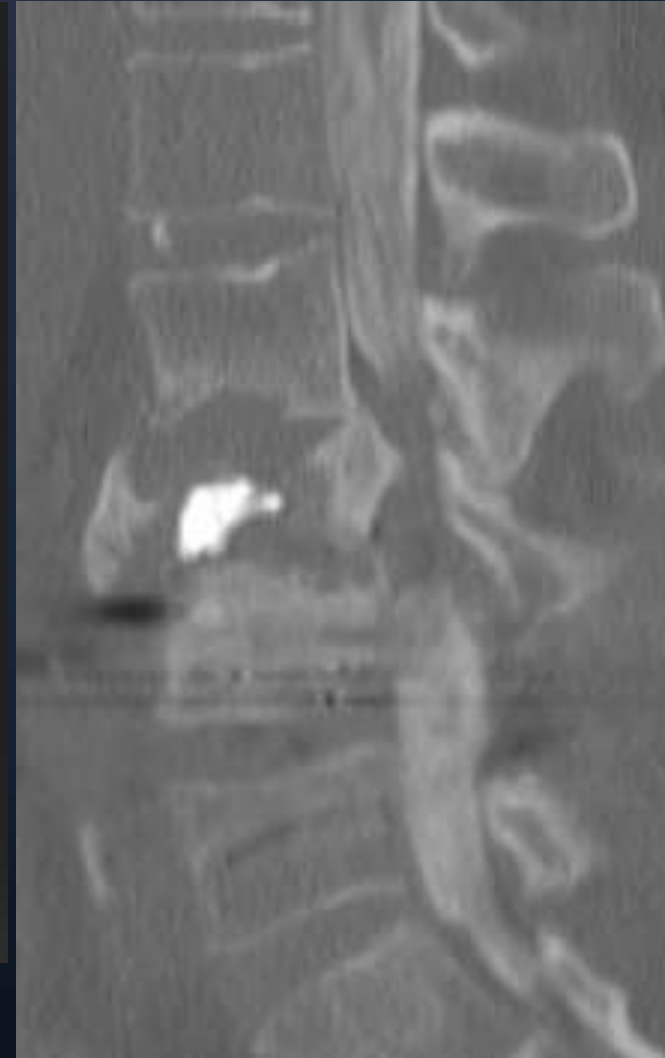
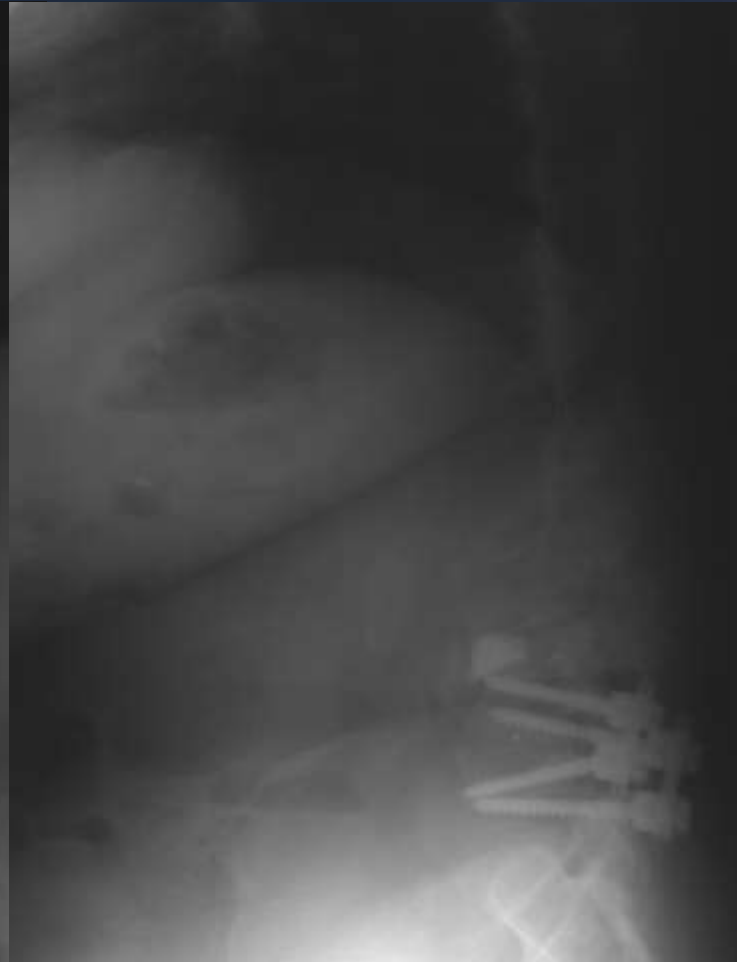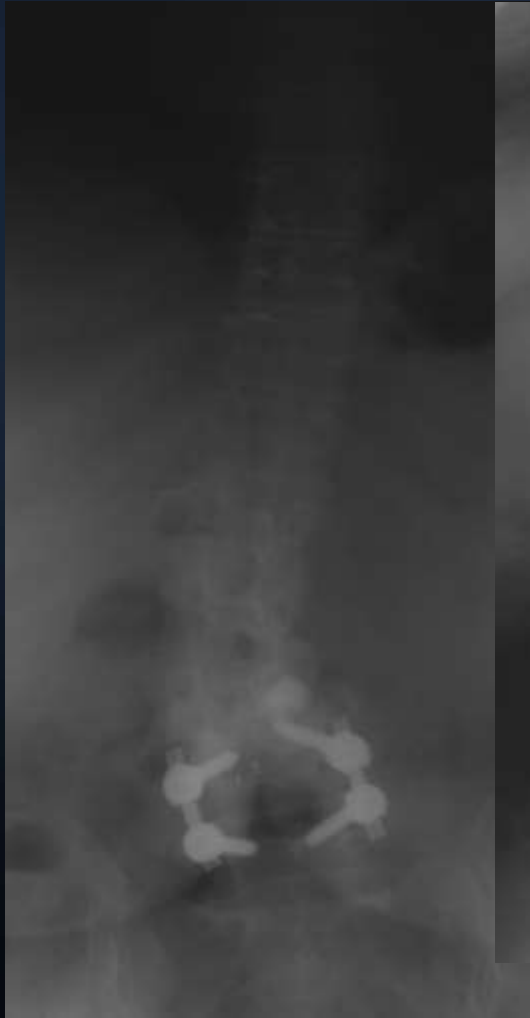# CASE 2



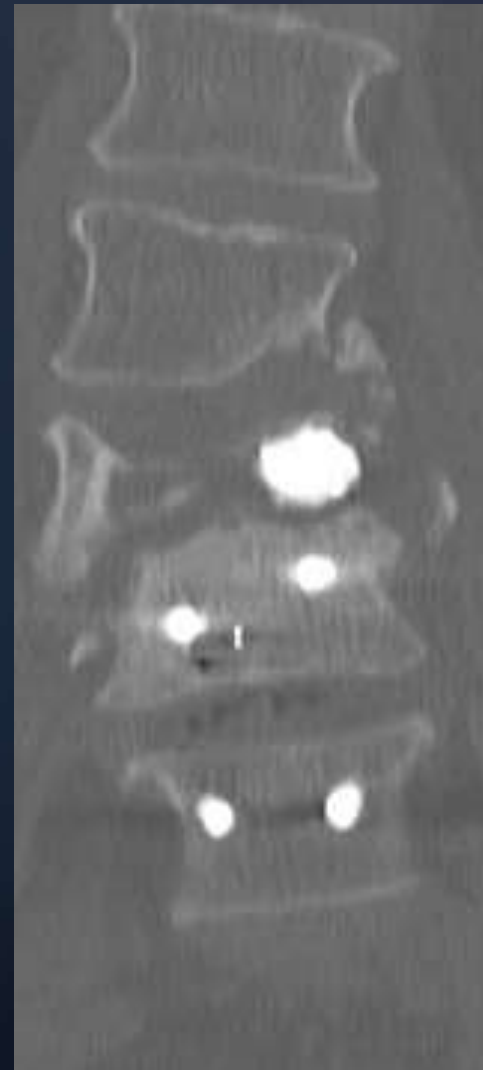
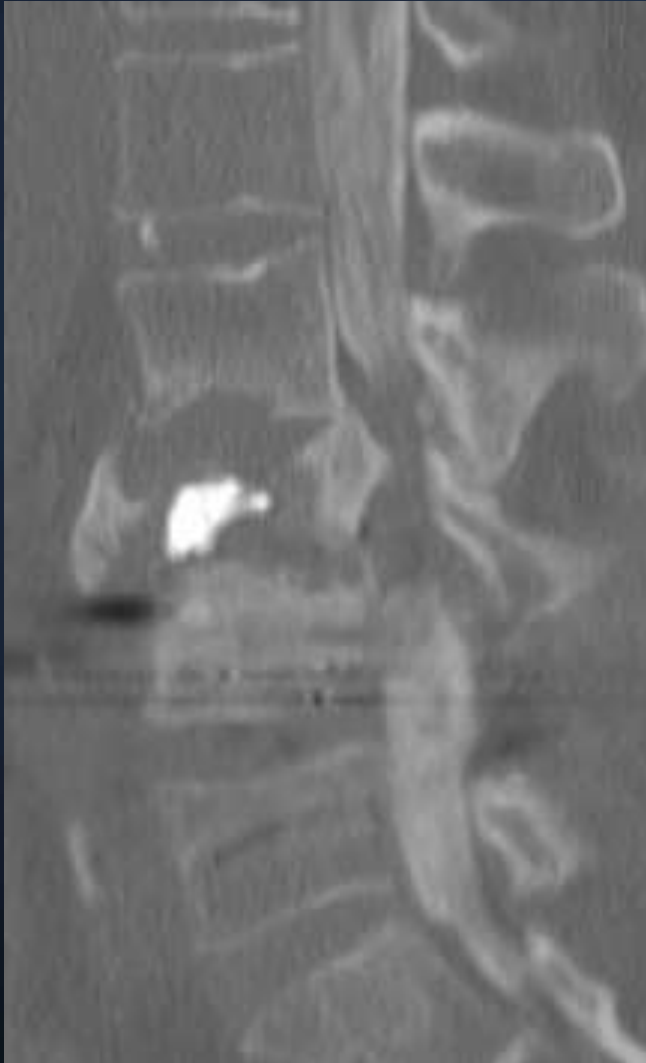# CASE 2



CASE 3 – 69 YO F W BURST FX, FAILED KYPHO,  
250#



CASE 5 – 59 YO F W BURST FAILED KYPHO,  
250#



# 59 YO 250# F W BURST FX TRANSPSOAS CORPECTOMY

