

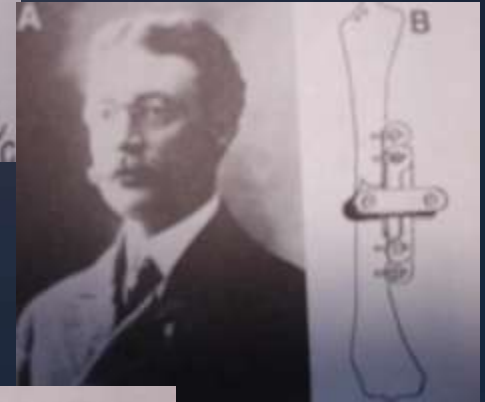



Hybrid and Spanning External Fixation

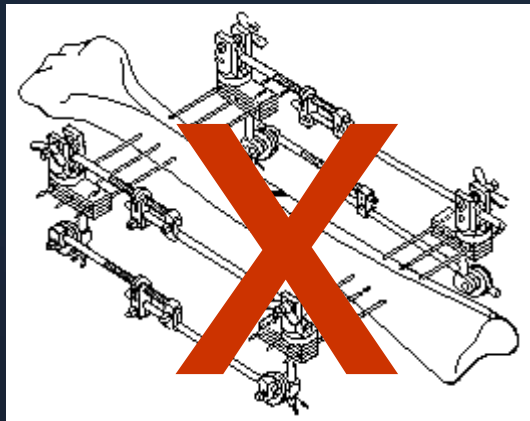
Wayne Cheng, MD
Bones and Spine

History

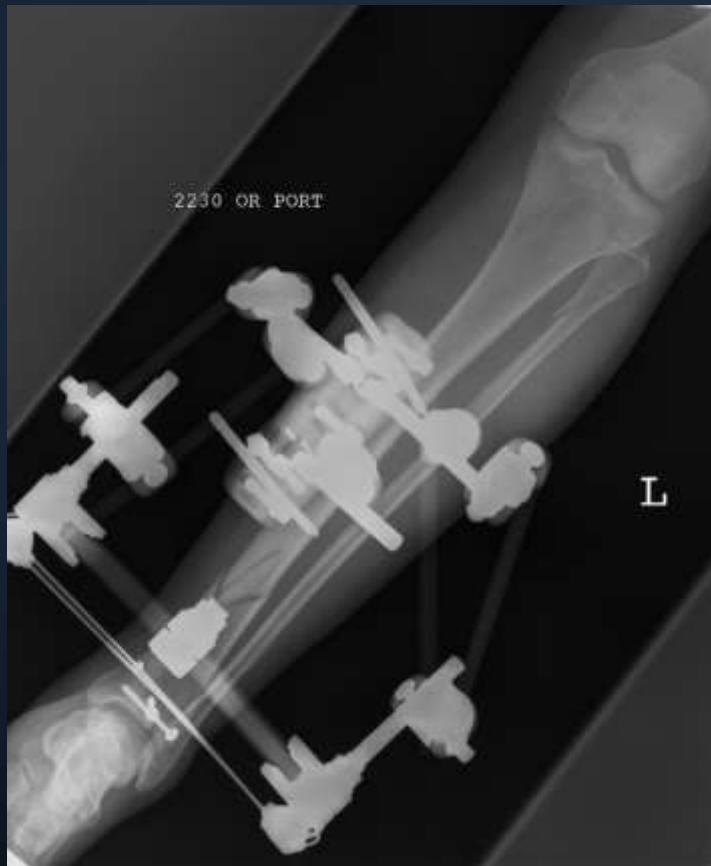- Jean-Francois Malgaigne, 1840
 - Malgaigne's point
 - Malgaigne's claw
- Clayton Parkhill, 1897
 - Bone clamp
- Lambotte
 - Lambotte ext fixator



1940 to 1970



Hybrid External fixator



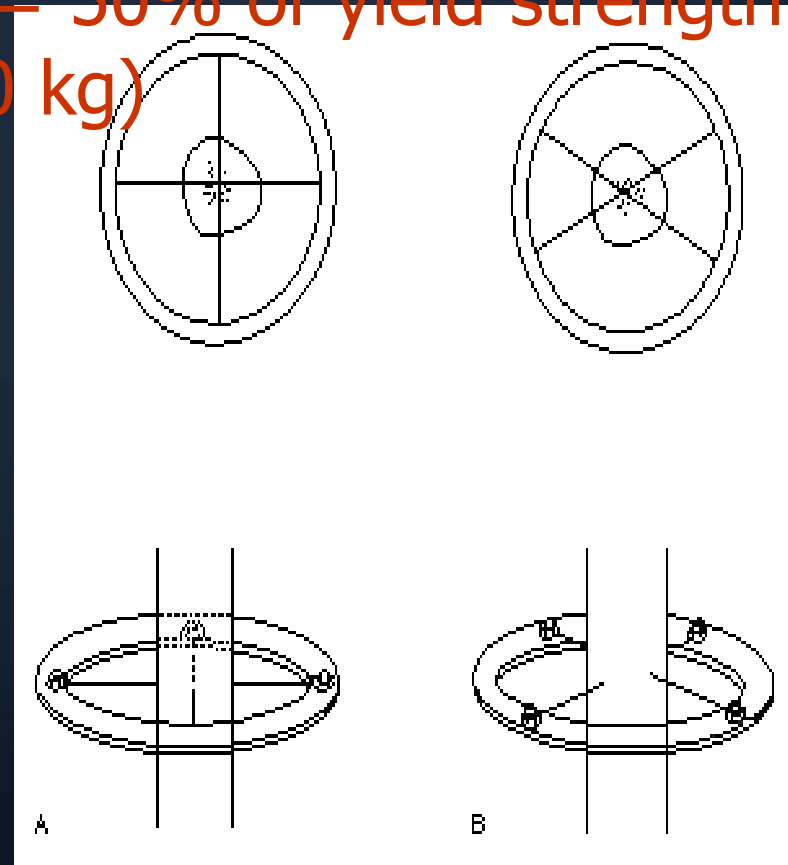
- Soft tissue reaction
- Affixing smaller metaphyseal fragm
- Cancellous bone
- Trampoline effect
- Half pins

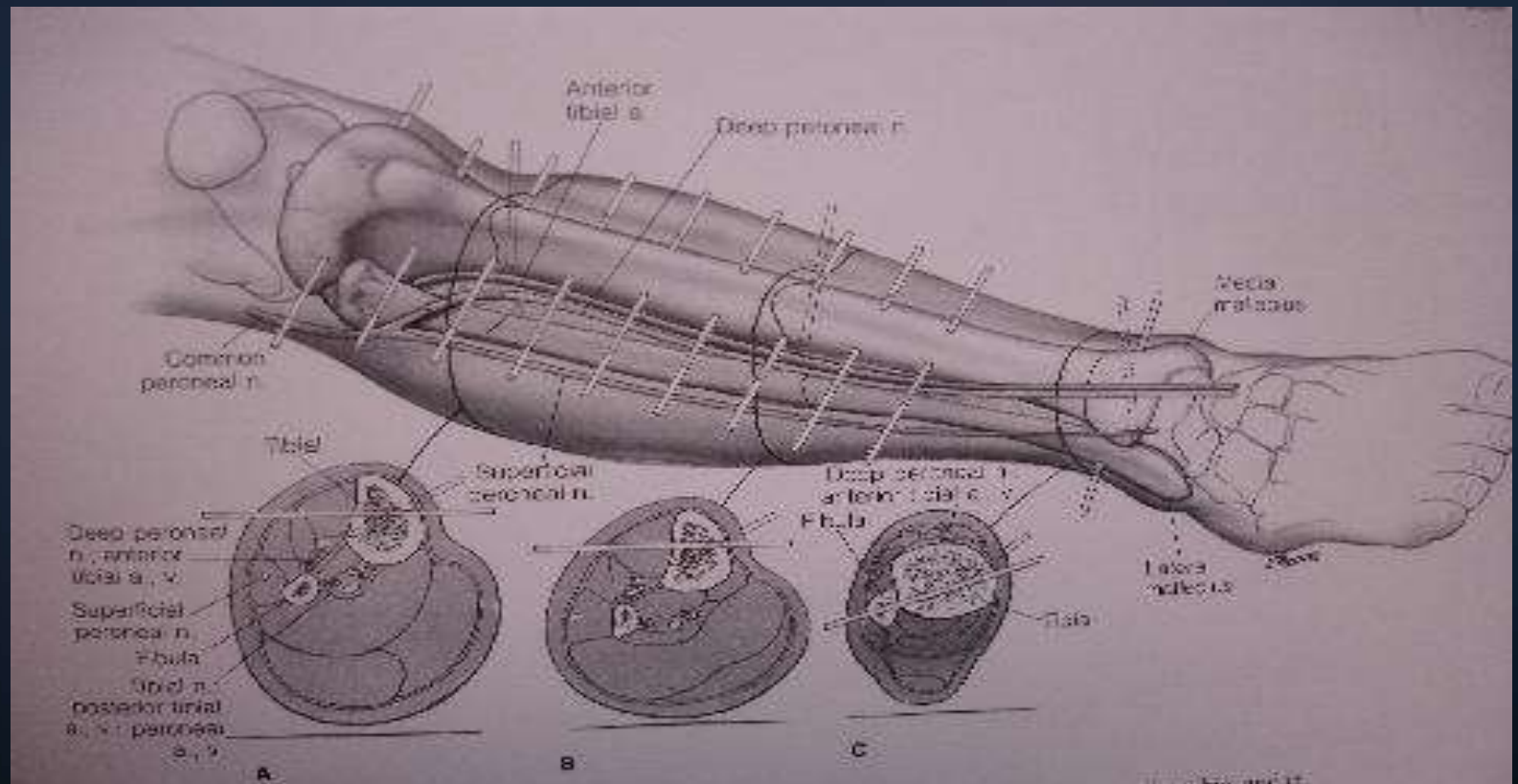
Biomechanics - stability

$$S = r^4$$

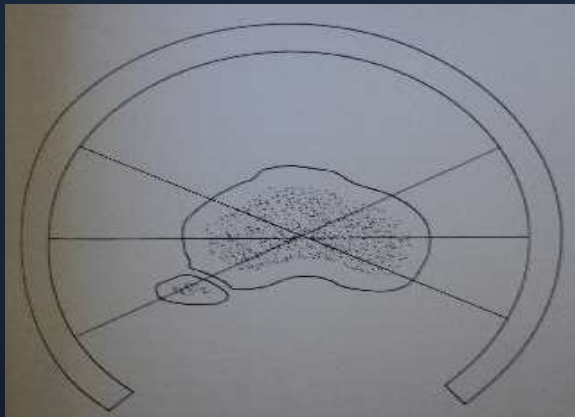
- Wire diameter
- Wire tension
- Crossing angle
- Distance ring to bone
- # of wire
- Olive wire
- Center bone

Optimal = 50% of yield strength
(80 – 90 kg)

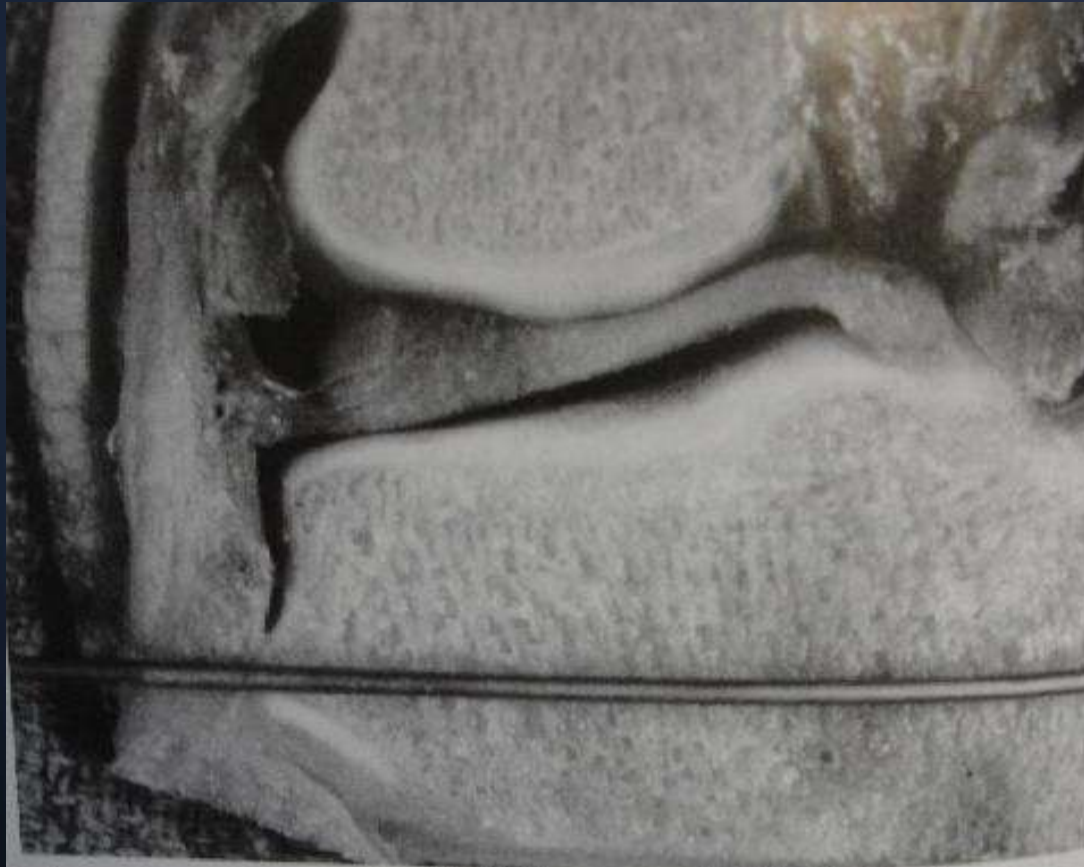




Location at proximal tibia



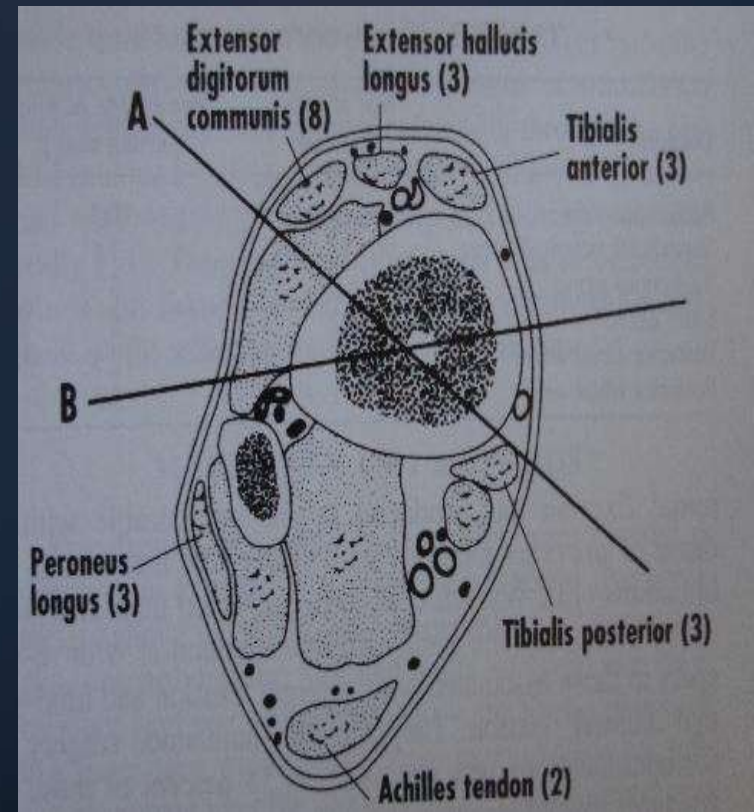
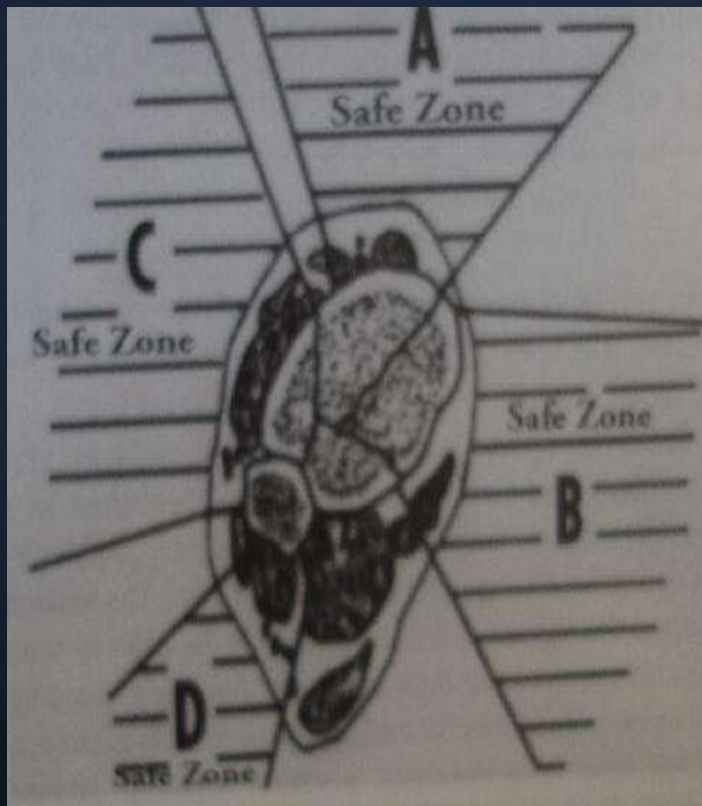
Knee capsular reflection



- 14 MM
- 10%

Spence Reid, MD

Safe corridors distal tibia

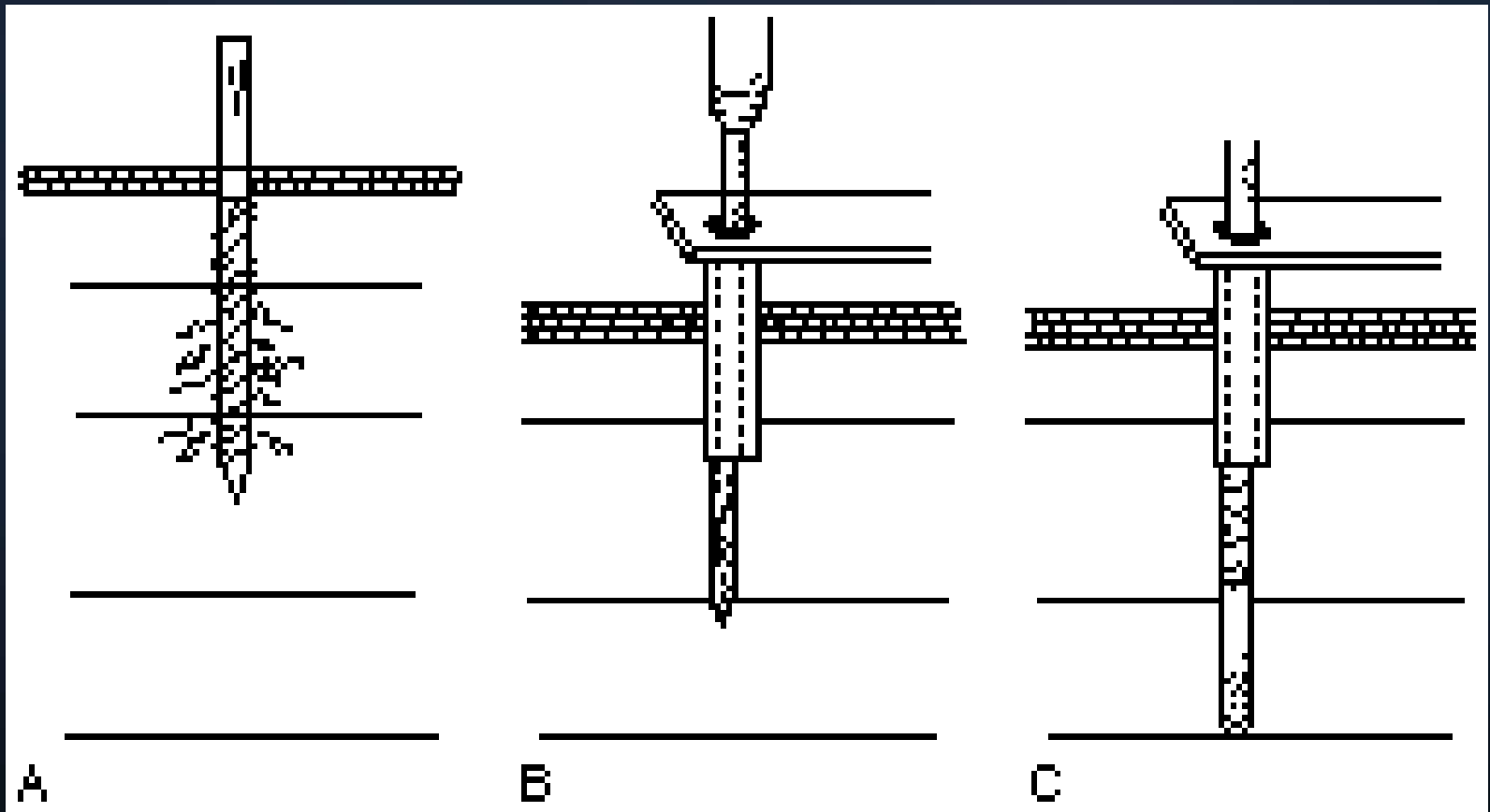


Ankle capsule

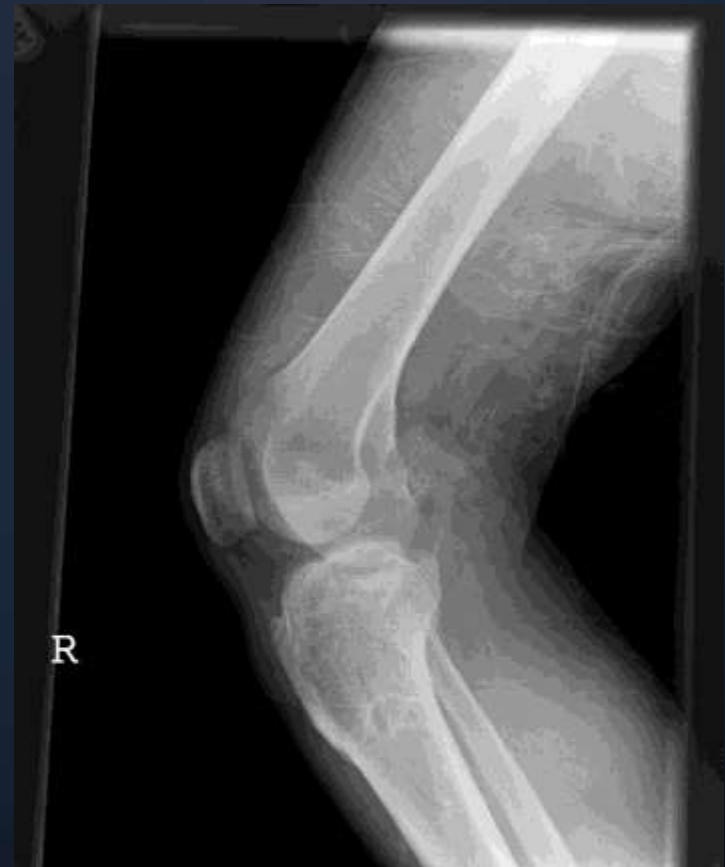
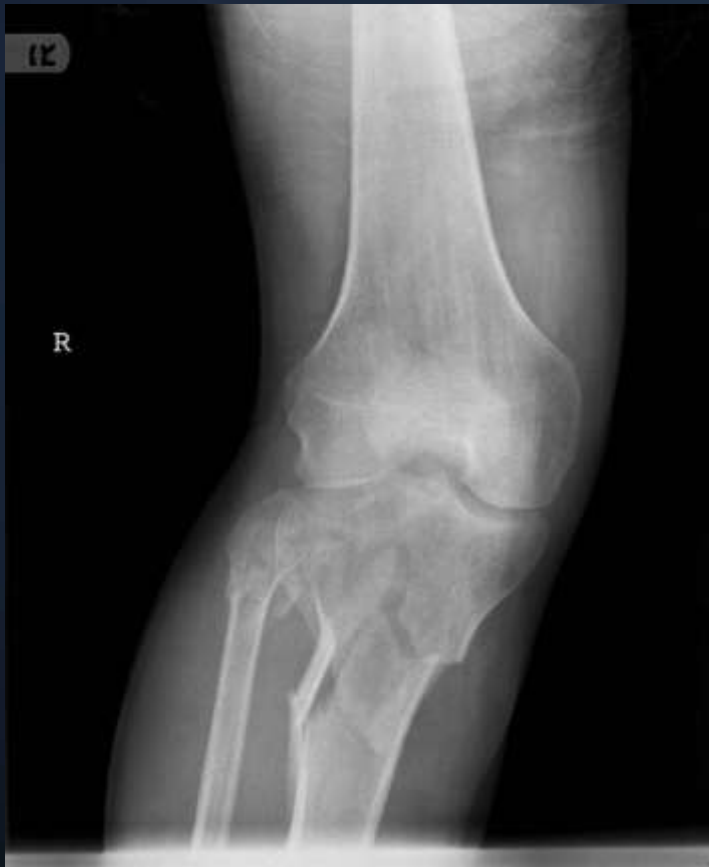
Superior capsular reflection 21 mm from antmed joint line

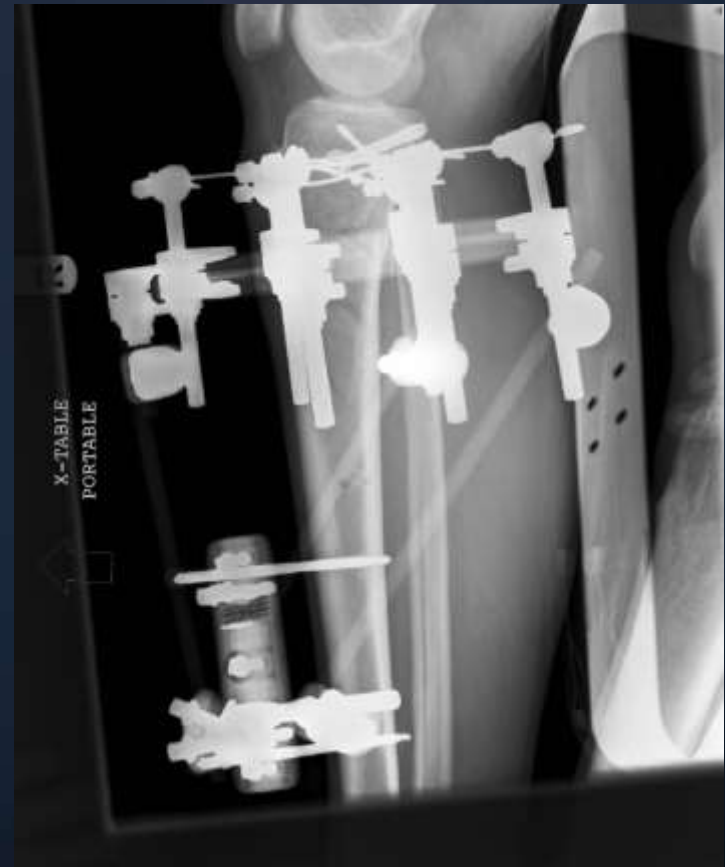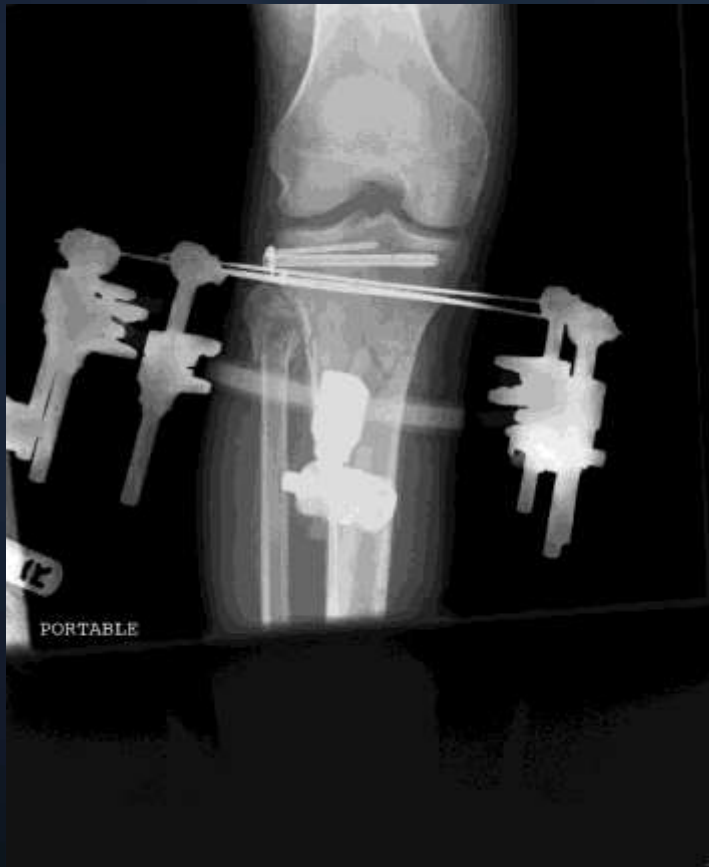Insertion technique



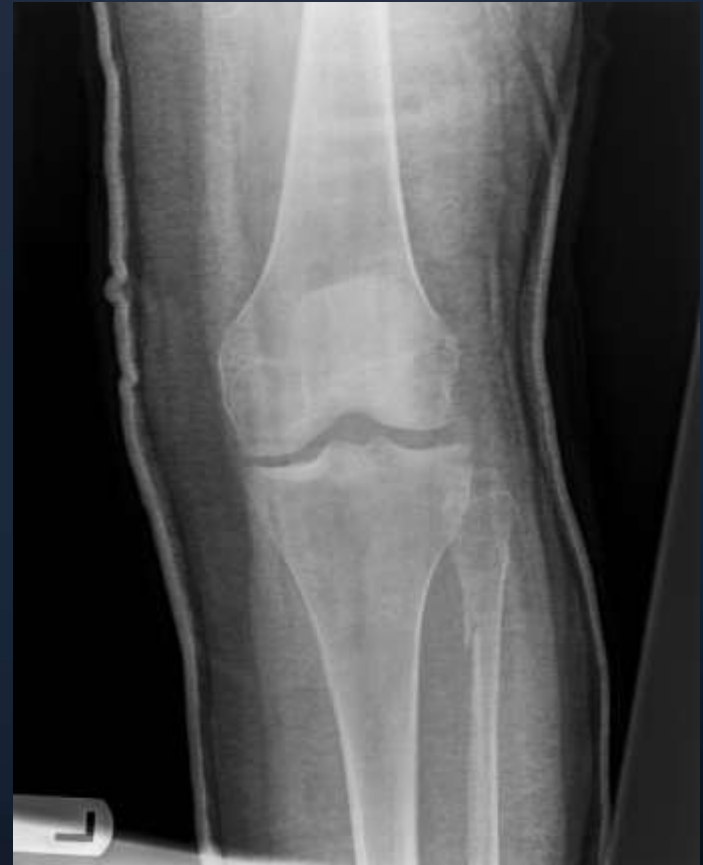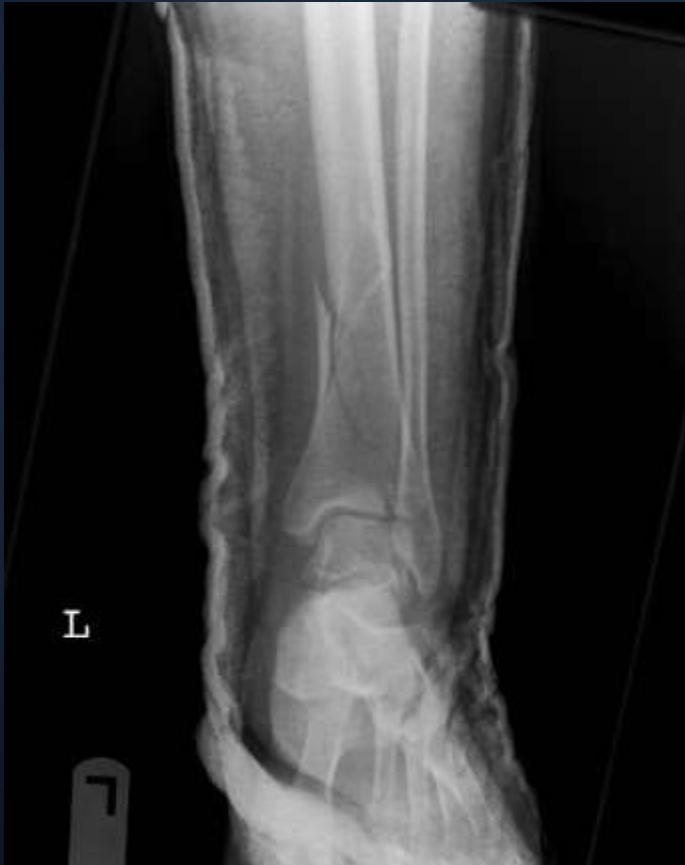Case example 1



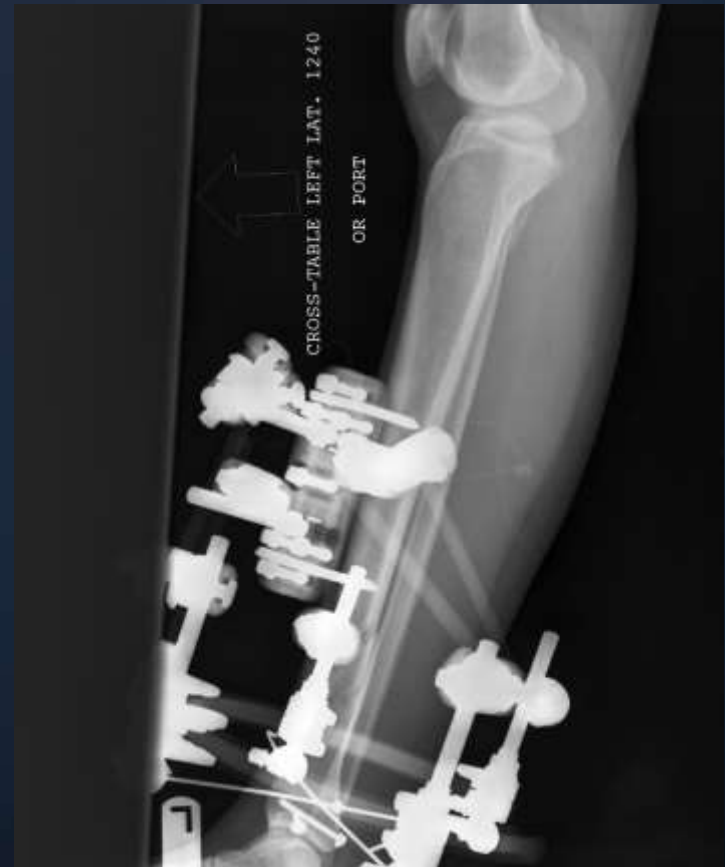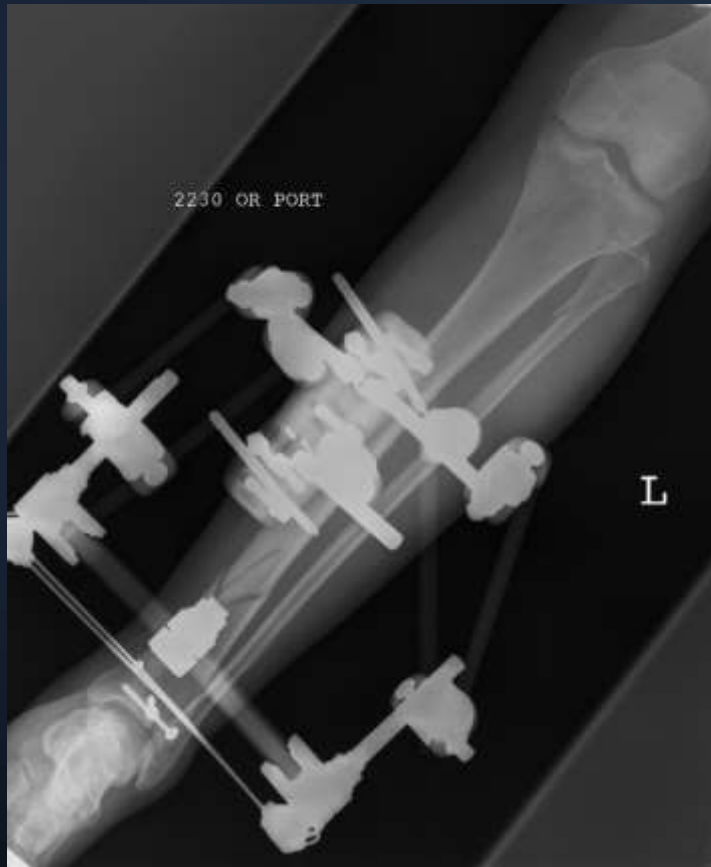Case example 1 – post op



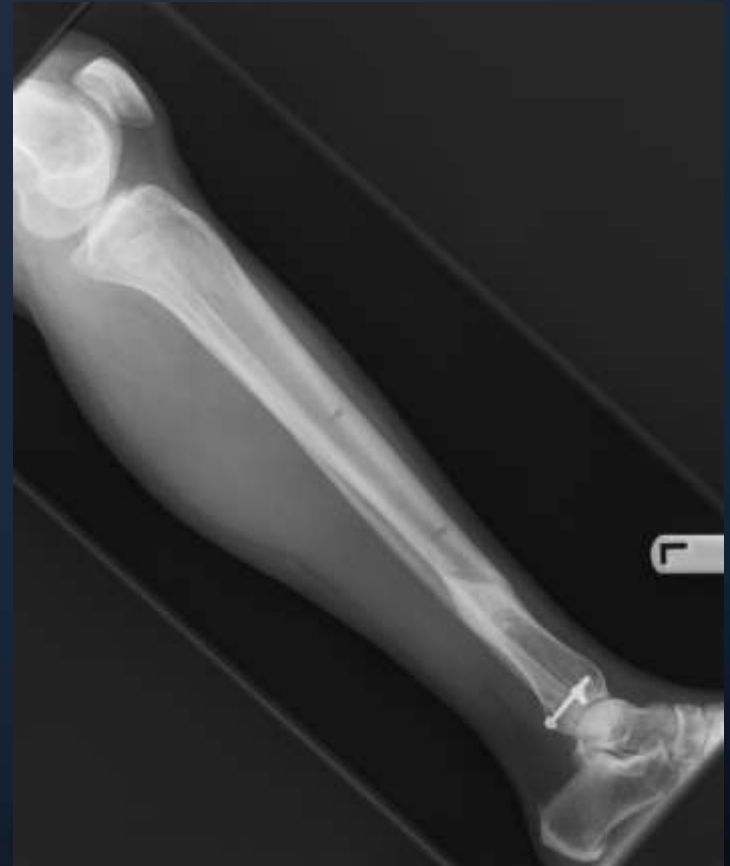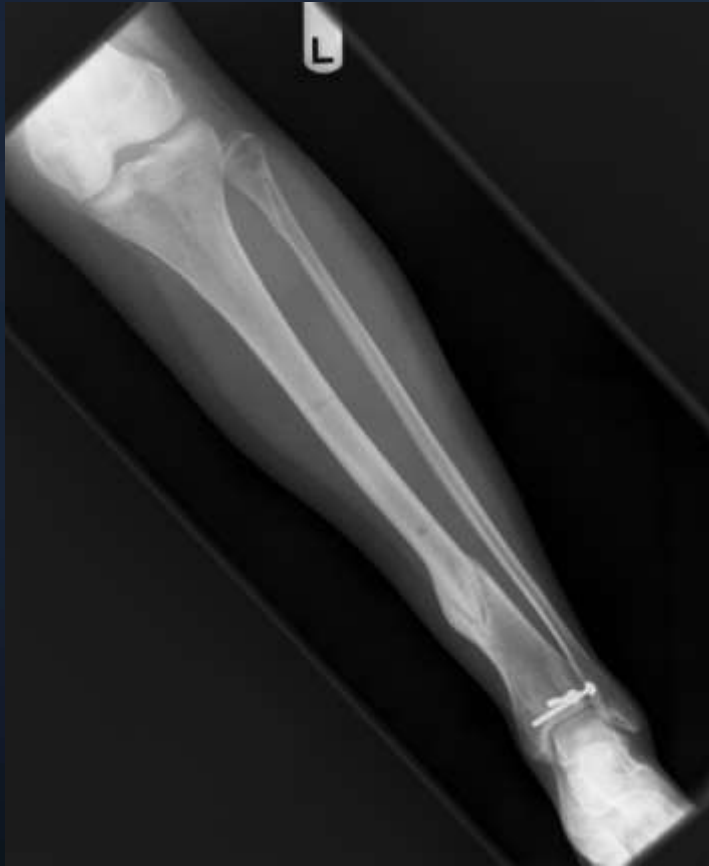Case 2



Case example 2



Case 2 - final



Is hybrid any good?

- 31 complex proxm tibia fx.
- 3.7 year f/u
- Functional grading (rasmussen)
 - 84% good
 - 12% fair
 - 3% poor
- Complication
 - 23% pin tract infx.
 - 1 AKA

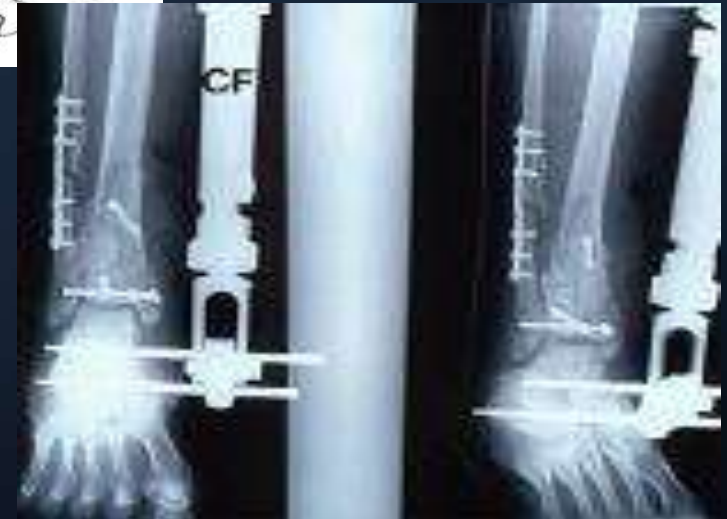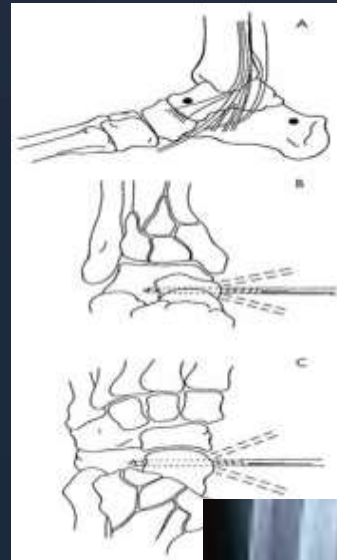
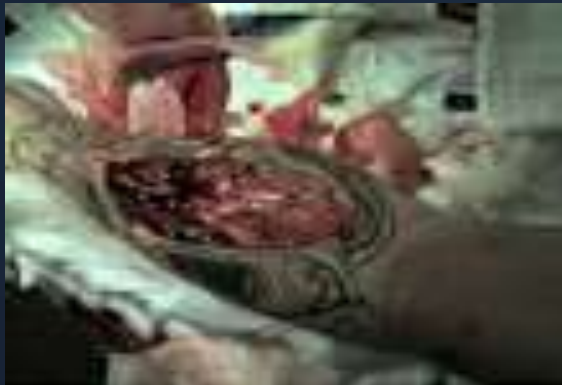Why did hybrid fall out of favor?

- High maintenance/malunion/nonunion
- Cumbersome/bulky
- Pin tract infection
- Meticulous insertion/assembly
- Fracture through pin sites
- expensive

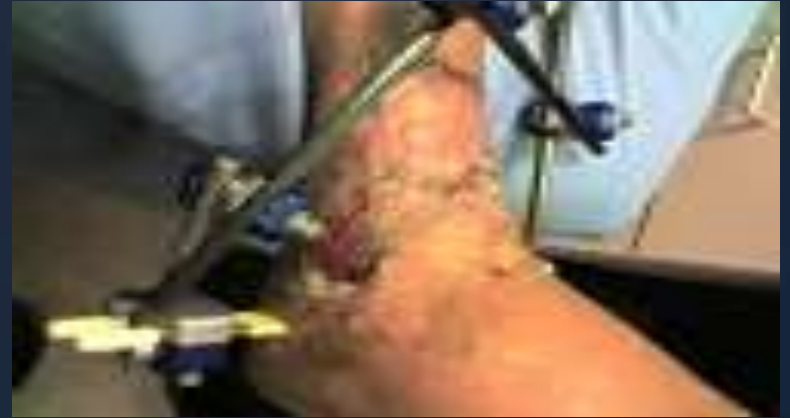Spanning External fixation + secondary internal fixation

<u><i>year</i></u>	<u><i>author</i></u>	<u><i>journal</i></u>	<u><i>#pts</i></u>	<u><i>Infx rate</i></u>
2005	Egol, Koval	JOT	62 plateau	5%
2004	Sirkin, sanderson	JOT	56 pilon	0% closed 11% open
2001	Dickson	Injury	35 pilon	8%

Spanning external fixation



Spanning external fixation



Conclusion

- Spanning external fixation is a valuable tool for initial soft tissue management
- 2nd stage internal fixation is attractive.
- Hybrid external fixation is a tool that may be valuable in selected cases.

THANK YOU