


# AxiaLIF



Wayne Cheng, MD

*Head of Spine Service*

*Professor, Department of Orthopedic Surgery*

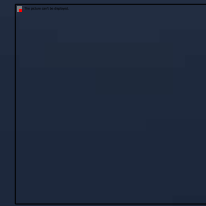

*Bones and Spine, Inc.*

# Intramedullary Nailing of Spine?

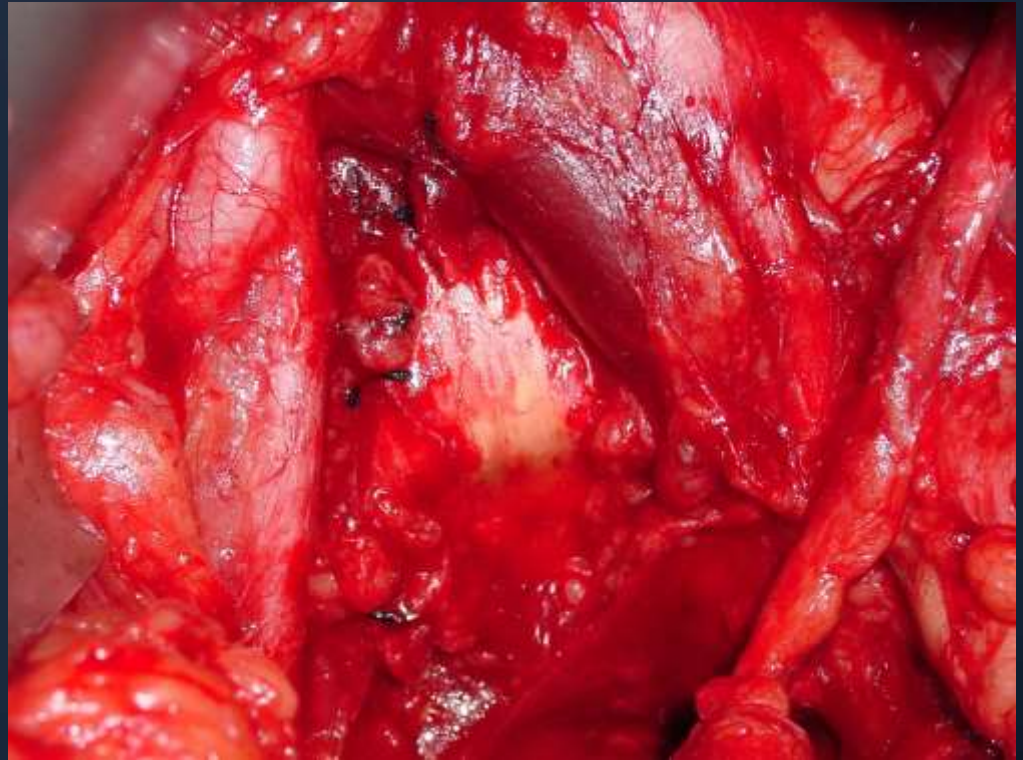


# Case 1

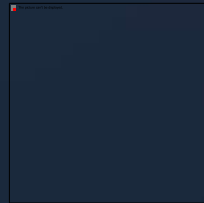
69 yo female, h/o multiple 8 prior back surg. W  
pseudo at at L5s1



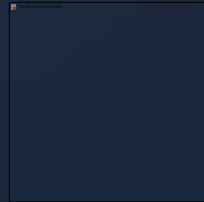
# Minimal Invasive?



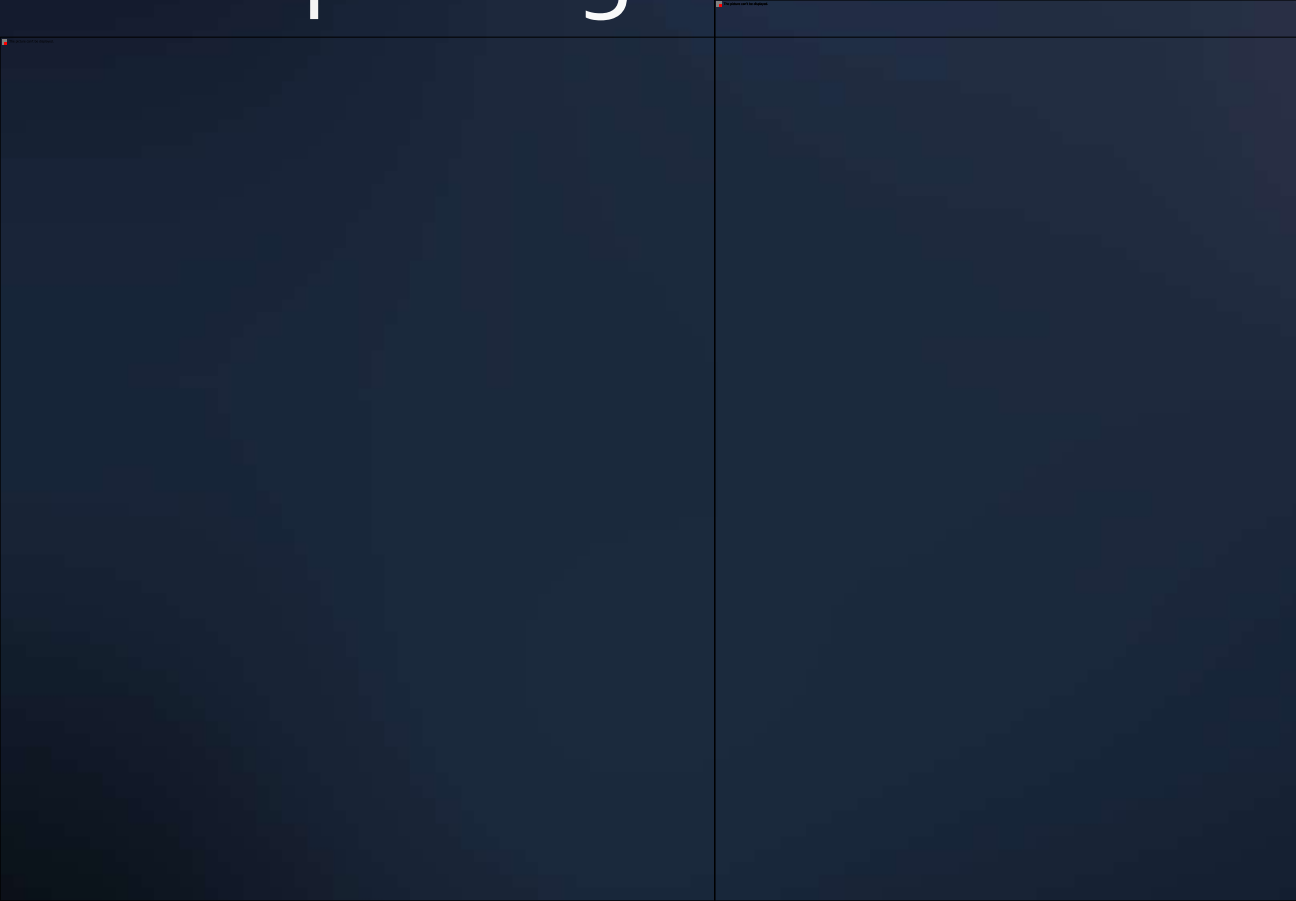
# Step 1 Access



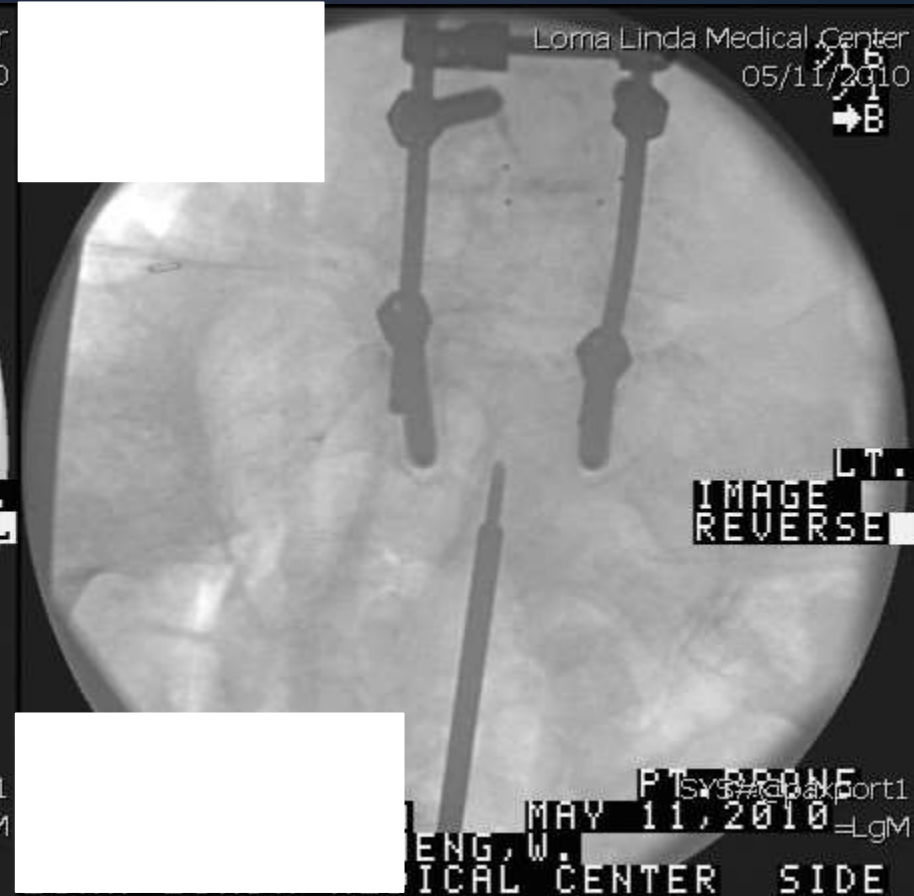
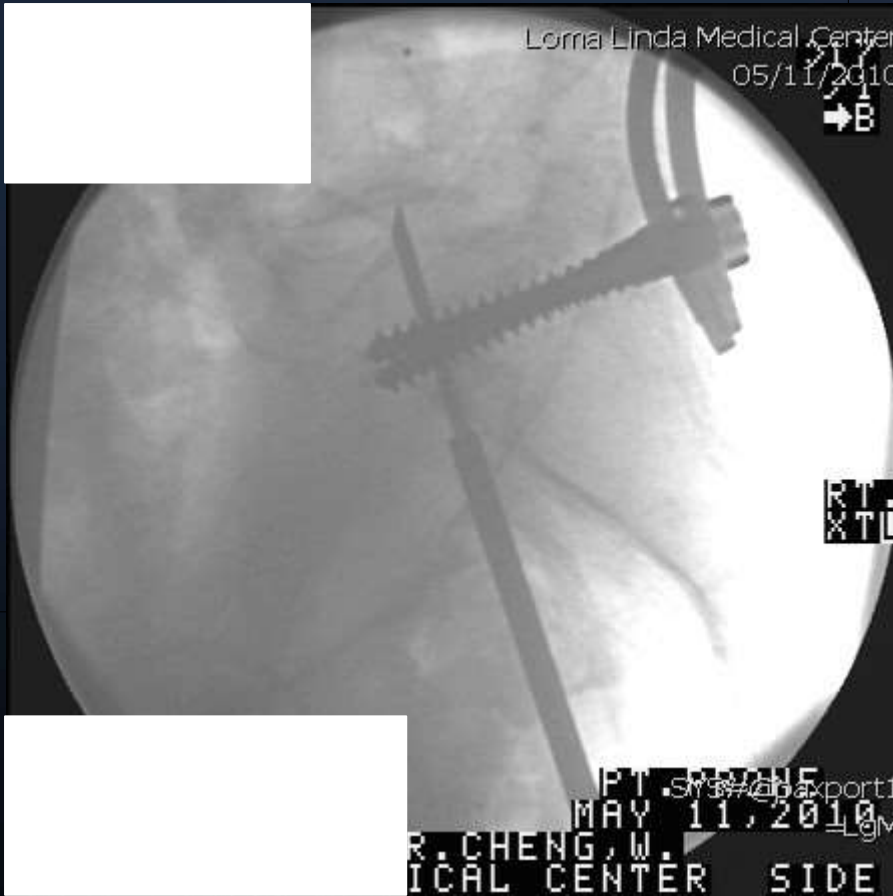
# Step 1-b finger palpation



# Step 1 - c guide



# Step 1-d guide wire





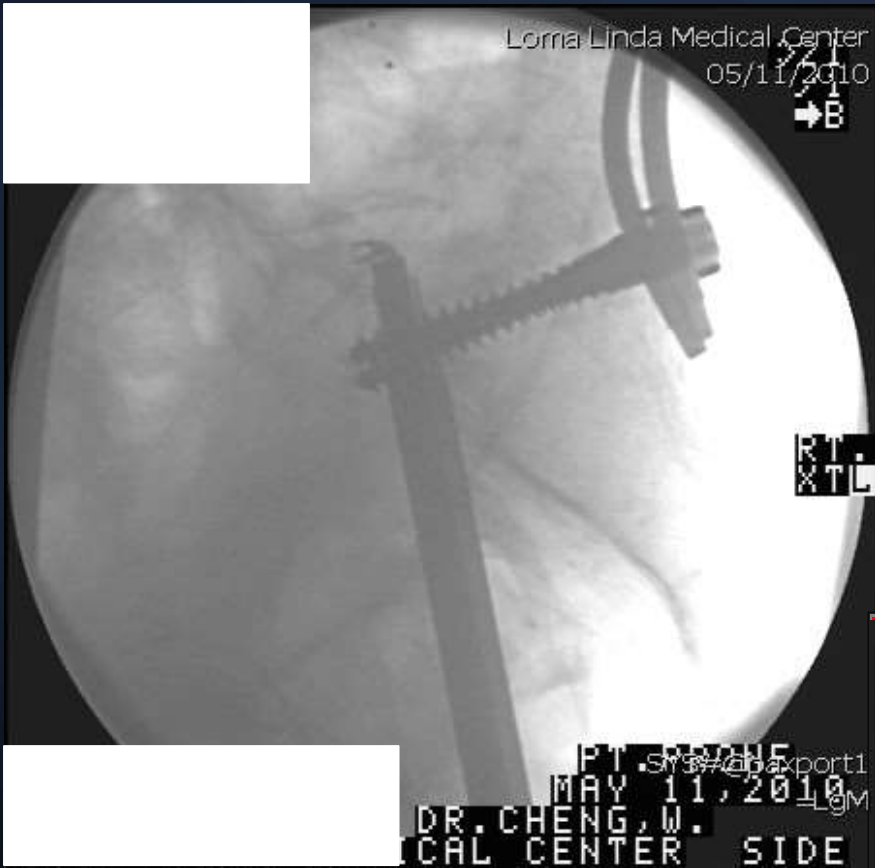




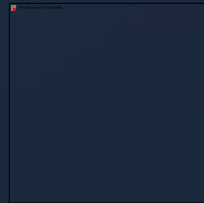
# Step 2-b drill S<sub>1</sub>



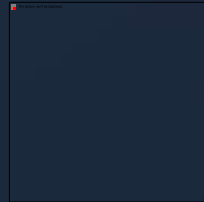
# Step 3-a Disc Prep



# Step 3-b bone graft/bmp

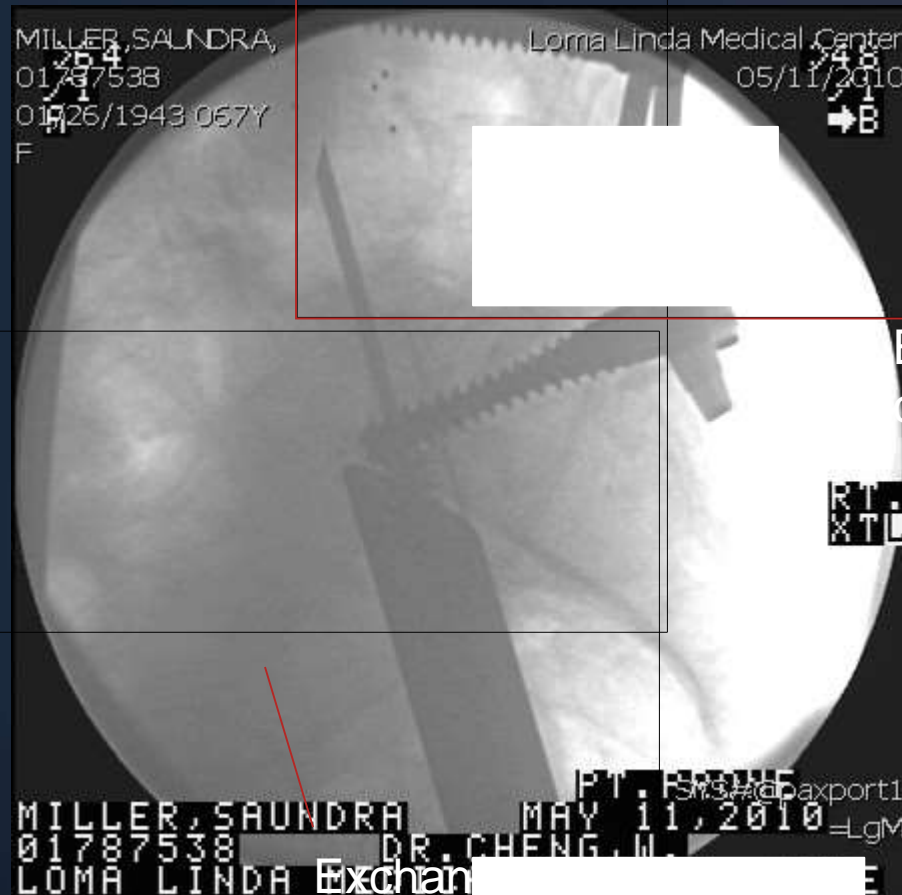


# Step 3-c drill L5

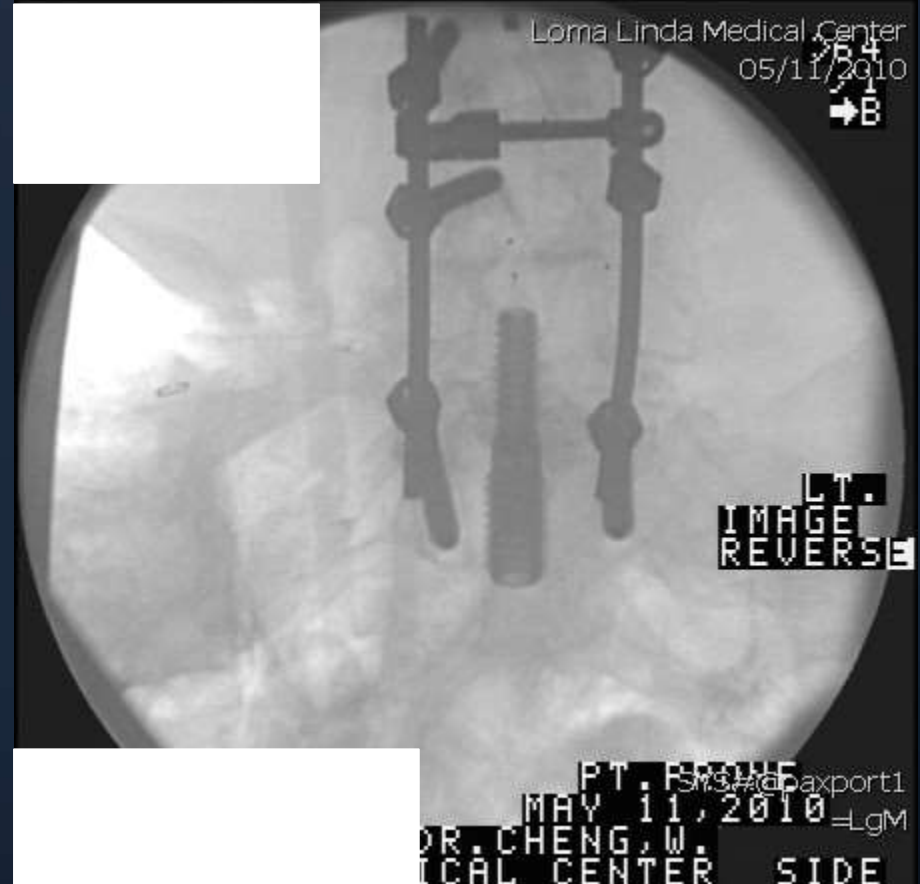
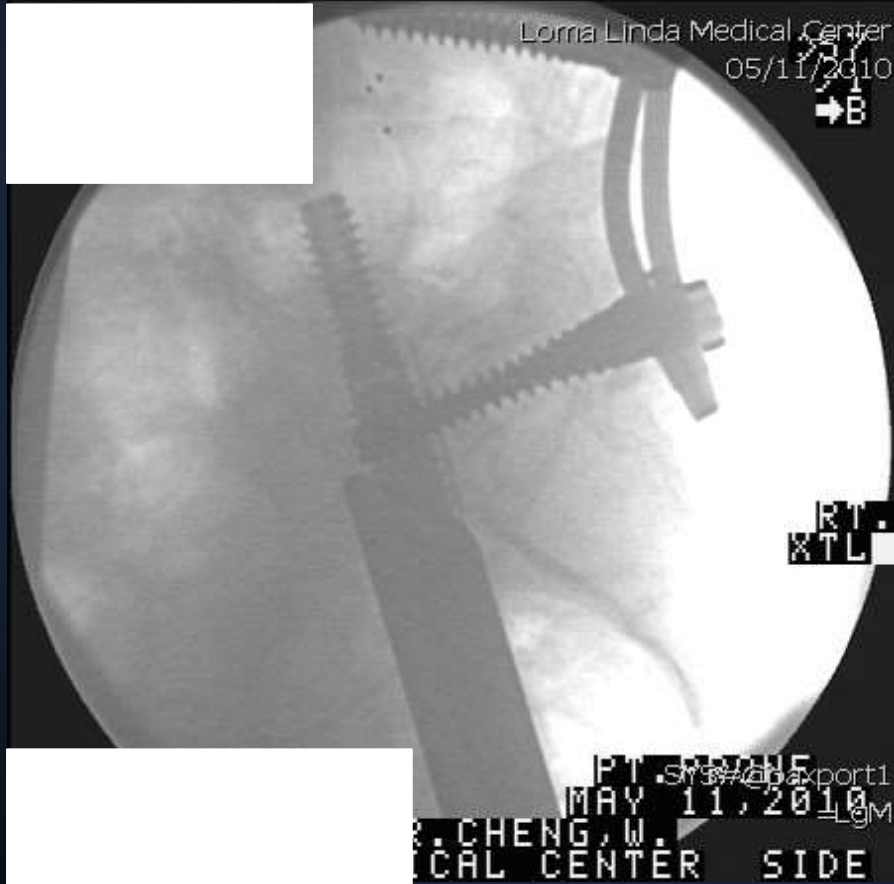




# Step 4 - b exchange Cannula

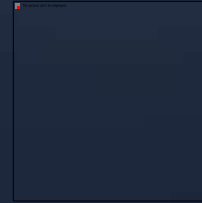
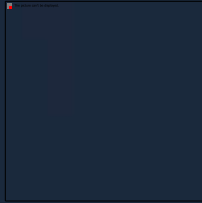


# Step 4-C Rod insertion





# Post op ap/lat xray



# COMPLICATION

