



Contents lists available at ScienceDirect

Journal of Clinical Neuroscience

journal homepage: www.elsevier.com/locate/jocn

Review

Survivorship and clinical outcomes after multi-level anterior lumbar reconstruction with stand-alone anterior lumbar interbody fusion or hybrid construct

Benjamin Chen^a, Yusuf T. Akpolat^b, Paul Williams^c, Darren Bergey^d, Wayne K. Cheng^{b,*}

^a MultiCare Orthopedics & Sports Medicine, Puyallup, WA, USA

^b Department of Orthopaedic Surgery, Loma Linda University Medical Center, 11406 Loma Linda Drive, Suite 213, Loma Linda, CA 92354, USA

^c Department of Pharmaceutical Science, School of Pharmacy, Loma Linda University, CA, USA

^d Back and Sport Institute, Newport Beach, CA, USA

ARTICLE INFO

Article history:

Received 12 August 2015

Accepted 11 October 2015

Available online xxxx

Keywords:

ALIF

Anterior lumbar interbody fusion

Hybrid construct

Multilevel lumbar degenerative disc disease

Total disc replacement

ABSTRACT

In multilevel disc disease, there is still uncertainty regarding whether multiple total disc replacement is more effective and safer than fusion. Our objective was to measure and compare the clinical outcome of multilevel hybrid constructs with stand-alone anterior lumbar interbody fusion (ALIF) using a retrospective analysis. Sixty-four patients with chronic low back pain determined to be from two or three-level degenerative disc disease were included. Thirty-three patients were treated with hybrid fusion and 31 with ALIF. Several parameters were retrospectively reviewed, including blood loss, operation time, hospital stay, Visual Analog Scale (VAS) score, Oswestry Disability Index (ODI), and survivorship without the need for revision surgery. Telephone follow-ups were conducted to ascertain survivorship, clinical outcomes (VAS, ODI) and patient satisfaction. Operation time was longer in the hybrid group ($p = 0.021$). The hybrid group showed a significant improvement in VAS and ODI with 52.2% and 50.0% improvement versus 28.3% and 25.5% in the ALIF group ($p < 0.05$). At the telephone follow-up for patient satisfaction, 95.7% ($n = 22$) of the hybrid group were satisfied and 95.2% ($n = 21$) of the ALIF group were satisfied. Seventy-four percent ($n = 17$) in the hybrid group and 85.7% ($n = 18$) in the ALIF group would choose to do the initial surgery again. Kaplan–Meier analysis showed 80.5% survivorship for hybrids and 75.9% for ALIF at 5 years. With our clinical outcomes in VAS and ODI scores, these results, when taken together, indicate that hybrid fusion is a valid and viable alternative to ALIF fusion, with at least equal if not better clinical outcomes in terms of survivorship, back pain, and disability scores.

© 2015 Elsevier Ltd. All rights reserved.

1. Introduction

Back pain affects roughly 50–80% of the population in a lifetime. It is second only to respiratory infection as the most common reason for doctor visits [1]. For severe disc degeneration with refractory pain, spinal arthrodesis is usually performed. Concerns persist over the long-term consequences of a rigid fusion on the remaining levels [2,3]. Longer fusion constructs carry increased risk for poor outcome [4]. Based on these concerns, there has been an increasing interest in motion preservation devices [5]. The advantage of an artificial disc is that it preserves motion at operated levels, and theoretically avoids excessive strains on the non-operated levels, which may lead to adjacent level disease.

In multilevel disc disease, there is still uncertainty regarding whether multiple total disc replacement (TDR) is more effective and safer than fusion. Siepe et al. observed that multilevel disc replacement with ProDisc (DePuy Synthes, West Chester, PA, USA) had significantly higher complication rates and inferior outcomes compared to single-level TDR [6]. Delamarter et al. published short-term results on two-level lumbar degenerative disc disease showing clinical advantages of TDR in terms of pain relief and functional recovery [7]. A limited number of studies showed mixed success of artificial disc surgery for multilevel disc disease.

An alternative to a multilevel disc replacement procedure is to apply a hybrid model by combining a fusion procedure at the caudal level and disc replacement at the level above. Erkan et al. showed that the motion at the TDR level in a hybrid mode was similar to that of two-level disc replacement [8]. To our knowledge there has only been one study that reported a clinical series of lumbar hybrid fusion [9]. In this study, we compared the clinical outcome

* Corresponding author. Tel.: +1 909 558 6444; fax: +1 909 558 6118.

E-mail address: md4spine@yahoo.com (W.K. Cheng).

of multilevel hybrid constructs with anterior lumbar interbody fusion (ALIF).

2. Materials and methods

A retrospective review of clinical and radiographic parameters of patients who had anterior lumbar reconstructive surgeries from November 2004 to August 2009 was conducted. These patients had two or three-level symptomatic lumbar degenerative disc disease. A total of 64 patients were identified who fulfilled the following inclusion and exclusion criteria. All patients underwent a left anterior retroperitoneal approach. Patients were treated at our university medical center by one of our two spine surgeons.

Degenerative disc disease was determined by history, physical examination, and radiographic studies. Our inclusion criteria for both hybrid and ALIF groups were patients between 18 to 65 years old, two or three-level degenerative disc disease with no instability or mild Grade I spondylolisthesis with mild or no signs of facet arthrosis, and both MRI and provocative discography concordant with imaging studies. Patients were excluded if they had any instability greater than Grade I spondylolisthesis, concurrent posterior fusion, major deformity (such as scoliosis greater than 15°), prior reconstructive surgeries (other than laminectomies or microdiscectomies), infection, or tumor.

2.1. Analysis of radiological parameters

We retrospectively reviewed preoperative radiological studies to evaluate for degenerative disc disease, using MRI to determine the presence of Modic changes at the endplates, as well as discography. We reviewed all available plain radiographs and CT scans postoperatively. For disc replacements, we analyzed the position of the artificial disc for device migration or subsidence ≥ 3 mm, implant loosening, and loss of disc height >3 mm. For ALIF, we looked at extent of fusion mass, implant position, and any radiographic signs of loosening.

2.2. Analysis of clinical parameters

We retrospectively reviewed preoperative clinical parameters including age, sex, operative time, estimated blood loss, need for intraoperative blood products, hospital stay, pre- and postoperative Visual Analog Scale (VAS) score for the back pain, and Oswestry Disability Index (ODI). We classified failure as return to the operating room for any subsequent operations on the lumbar spine such as removal of malpositioned implants, additional fusion at the index level, pain pump placement, revision surgery for pseudarthrosis, and additional fusion for adjacent level disease. We set failure as an endpoint. In patients who did not fail according to their records from the initial surgery, a telephone follow-up was completed to ascertain if any further lumbar spine surgeries were performed, as well as the most current VAS, ODI, patient satisfaction, and perceived improvement of symptoms.

2.3. Statistical analysis

Statistical analysis was performed using the Statistical Package for the Social Sciences (IBM, Armonk, NY, USA). Significance of differences between data sets was calculated using the t-test. The incidence for surgical intervention after index surgery was calculated. Kaplan–Meier survivorship curve with 95% confidence intervals was constructed. For patient responses in the follow-up survey, a chi-square test for significance was performed.

3. Results

Sixty-four patients who matched our criteria were found. Of these, 33 patients (13 men, 20 women) were identified who underwent hybrid fusion (Fig. 1) and 31 patients (six men, 25 women) were identified who underwent two or three-level ALIF (Fig. 2). The hybrid group had one patient with a prior single-level lumbar laminectomy, while the ALIF group had one patient with a prior single-level laminectomy and one patient with a single-level microdiscectomy.

In the 25 (76%) patients who underwent two-level hybrid fusions, ALIF was performed at the caudal level and disc replacement at the cephalad level. For the eight (24%) patients who had three-level hybrid fusions, five patients had one disc at the most cranial level and two ALIF on caudal levels, while the remaining three patients had two disc replacements and one ALIF at the most caudal level. In the ALIF group, 25 (81%) had two-level fusion while six patients (19%) had three-level fusions. This data is summarized in Table 1.

3.1. Clinical outcome

The clinical outcomes are summarized in Table 2–4. Patients were significantly younger in the hybrid group with an average age of 42.8 years versus 49.7 years in the ALIF group. Operative time was also substantially increased in the hybrid group. No statistical differences were noted in blood loss and hospital stay (Table 2).

Forty-one patients who had both preoperative and postoperative VAS and ODI were found. Of these, 16 were in the hybrid group, and 25 were in the ALIF group. The VAS for back pain is presented in Table 3. All 41 patients in this study presented with low back pain with a mean preoperative score of 6.7 (standard deviation [SD]:2.3) in the hybrid group and 6.7 (SD:0.98) in the ALIF group. The mean VAS for back pain decreased to 3.2 (SD:2.2) postoperatively in the hybrid group versus 4.8 (SD:1.03) in the ALIF group. The improvement for hybrid and ALIF groups was 52.2% versus 28.3%, respectively ($p = 0.038$).

The ODI is presented in Table 4. In the hybrid group, mean preoperative ODI decreased from 55.0 (SD:18.4) to 27.5 postoperatively (SD:22.7). In the ALIF group, mean preoperative ODI decreased from 58.3 (SD:6.1) to 43.4 (SD:7.8) postoperatively. The improvement was statistically higher in the hybrid group at 50% versus the ALIF group at 25.5% ($p = 0.049$).

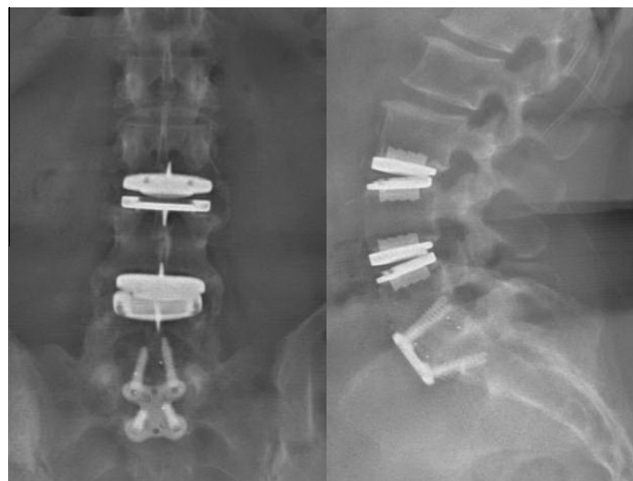


Fig. 1. (Left) Anteroposterior and (right) lateral radiographs showing hybrid fusion with a combination of anterior lumbar interbody fusion and total disc replacement.

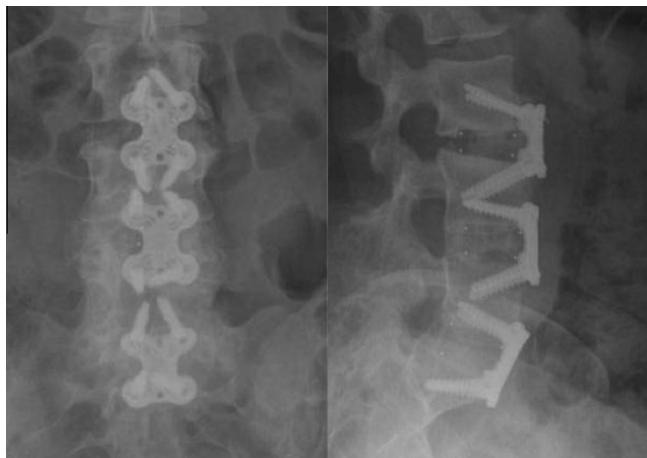


Fig. 2. (Left) Anteroposterior and (right) lateral radiographs showing multilevel anterior lumbar interbody fusion.

Table 1

Procedure levels for hybrid versus ALIF groups

Hybrid procedure (n = 33)	
Single-level ALIF + single-level TDR	25
Two-level ALIF + single-level TDR	5
Single-level ALIF + two-level TDR	3
ALIF procedure (n = 31)	
Two-level	25
Three-level	6

ALIF = anterior lumbar interbody fusion, TDR = total disc replacement.

Table 2

Objective outcomes of hybrid and ALIF groups

	Hybrid	ALIF	p value
Sex			0.08
Male	13	6	
Female	20	25	
Mean age (years)	42.8	49.7	0.01
OR time (hours)	5:01	4:16	0.02
EBL (cc)	356	217	0.09
Hospital stay (days)	5.1	4.6	0.27

ALIF = anterior lumbar interbody fusion, EBL = estimated blood loss, OR = operation.

Table 3

Preoperative and postoperative VAS scores for back pain in hybrid and ALIF groups

	Preoperative VAS	Postoperative VAS	Improvement
Hybrid (n = 16)	6.7 ± 2.3	3.2 ± 2.2	52.2%
ALIF (n = 25)	6.7 ± 0.98	4.8 ± 1.03	28.3%
p value			0.038

Data are presented as mean ± standard deviation.

ALIF = anterior lumbar interbody fusion, VAS = Visual Analogue Scale.

3.2. Failures

Of the two groups, the hybrid group had seven cases out of 33 that failed and required another procedure subsequent to the index operation. One patient had a construct with two TDR above L5–S1 fusion, who developed scoliosis to the right with tilting of TDR 1 week after the index surgery. The patient was taken back for revision surgery and conversion to a three-level ALIF. Another case was a two-level construct, where the TDR migrated early and was revised 5 days after index surgery. There were two other cases of migration revised to a posterior fusion construct after the TDR migrated to protrude anteriorly at 5.1 months and

Table 4

Preoperative and postoperative ODI scores for hybrid and ALIF groups

	Preoperative ODI	Postoperative ODI	Improvement
Hybrid (n = 16)	55.0 ± 18.4	27.5 ± 22.7	50.0%
ALIF (n = 25)	58.3 ± 6.1	43.4 ± 7.8	25.5%
p value			0.049

Data are presented as mean ± standard deviation.

ALIF = anterior lumbar interbody fusion, ODI = Oswestry Disability Index.

8.5 months after index surgery. Two patients had revision surgery for pain at 14.1 months and 28 months. One patient had posterolateral fusion for pseudoarthrosis at 62.5 months.

In the ALIF group, there were a total of five failures out of 31 patients. Two patients had extension of their fusion for adjacent level degeneration at 8.9 months and 40.1 months after the index surgery. Two other patients had revision surgery for pseudoarthrosis at 27.2 months and 47.7 months. One patient had intractable pain that developed 59.6 months after index surgery and had a spinal stimulator placed.

3.3. Follow-up survey

Telephone surveys were conducted with patients who had disease-free survival (revision surgery) from the index surgery. A total of 23 hybrids (of 26) and 21 ALIF (of 26) patients responded. We had eight patients lost to follow-up (12.5%). The results are summarized in Table 5. Patients in both groups showed similar rates of satisfaction with index surgery (95.7% hybrids versus 95.2% ALIF). In the hybrid patients, 73.9% would choose to do the surgery again if given the choice and 86.4% felt that their back pain had improved. In the ALIF group, 85.7% would choose the index surgery again and 78.9% had perceived improvement in their back pain.

3.4. Survival outcome

Kaplan–Meier survivorship analysis was performed in order to assess the rate of disease-free survival (revision surgery) for the entire series of patients, and to take into account patients who had been lost to follow-up (Fig. 3). The estimated rate of disease-free survival was 80.5% in the hybrid group at 5 years after index operation versus 75.9% in the ALIF group ($p = 0.521$). This results shows that 19.5% of all patients who have had a hybrid fusion will have new disease warranting a second procedure within 5 years, which was comparable to the 24.1% in the ALIF group.

4. Discussion

Traditional fusion has long been the standard for treating refractory back pain due to degenerative disc disease in the lumbar spine. It is thought that the fusion between adjacent spine segments eliminates the back pain generators, including those resulting from disc, facet joints, and neural elements. The clinical outcome of fusions varies widely in the literature. In a meta-analysis study, Geisler et al. showed a mean decrease of back pain of 45.5% and mean ODI score of 27.9 [10].

Table 5

Patient satisfaction for hybrid and ALIF groups

	Hybrid	ALIF	p value
Satisfied with surgery	22/23 (95.7%)	20/21 (95.2%)	0.94
Would choose to have surgery again	17/23 (73.9%)	18/21 (85.7%)	0.33
Improved back pain	19/22 (86.4%)	15/19 (78.9%)	0.52

ALIF = anterior lumbar interbody fusion.

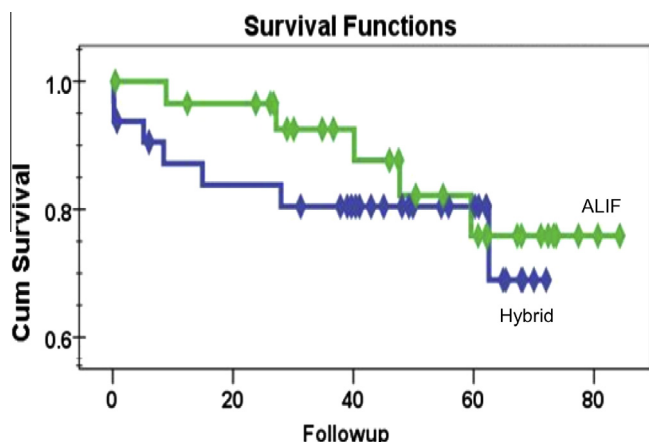


Fig. 3. Kaplan-Meier survivorship analysis for the hybrid and ALIF groups. ALIF = anterior lumbar interbody fusion, Cum = cumulative.

In recent years, surgeons have begun to turn to alternatives for treating refractory degenerative disc disease, that is from fusion to motion preservation devices. There is evidence that fusion constructs alter sagittal balance and contribute to undesirable complications in the long-term, including as failed back syndrome and adjacent segment disease. Several studies on TDR have shown outcomes that compare favorably with fusion, particularly for single-level disease [11,12]. For two-level TDR, there is evidence to suggest a higher risk of facet joint arthropathy and poorer outcome when compared to single-level TDR [6]. The hybrid fusion combines the advantages of ALIF with disc arthroplasty.

Examination of the perioperative parameters revealed that only operative time differed significantly between the two groups, while blood loss and postoperative hospital stay did not. The operative time was 45 minutes longer for the hybrid group. There is definitely a learning curve in the placement of TDR.

To our knowledge there was only one clinical study at the time of writing reporting outcomes after lumbar hybrid fusion. Aunoble et al. reported a mean postoperative ODI of 22.1 and 53.2% improvement after 2 years. The mean postoperative VAS score was 2.5 with a 64.6% improvement [9]. The hybrid group in our study compares similarly with the results published in this series, with a mean postoperative ODI score of 27.5 and 50% improvement. The mean postoperative VAS score was 3.2 with a 52.2% improvement.

In this study, the ALIF group showed a more modest improvement than some of what has been published in the literature [10,13]. We had only a 28.3% improvement in VAS and 25.5% improvement in ODI. This result is inferior to a prior meta-analysis by Geisler et al. [10]. This may be due to the fact that prior studies were focused only on a single-level, with mixed techniques including ALIF, posterior lumbar interbody fusion, and transforaminal lumbar interbody fusion in their data. In a recent study from Lammi et al., they included 81 single-level and 37 two-level ALIF in their study. Their average ODI difference combining both single and two-level ALIF was 17%, which is more consistent with our data.

The decision to perform ALIF alone *versus* hybrid was simple. Both options were explained to patients. The majority of the patients who had ALIF alone were covered by an insurance company that considered spine arthroplasty experimental, and therefore would only approve ALIF but not hybrid surgery. It is possible that the lower rate of improvement from ALIF patients may reflect the patient's disappointment with their insurance company's decision.

At the telephone follow-up, both groups responded similarly without statistically significant differences, demonstrating that greater than 90% in both groups were satisfied with surgery. Seventy-four percent in the hybrid group and 85.7% in the ALIF group would choose to do the initial surgery again. Eighty-six percent of hybrid and 78.9% of ALIF patients reported improvement of initial back pain.

In the follow-up for the survivorship data at 5 years, the predicted disease-free survival after index surgery was 80.5% for hybrid patients or 75.9% for ALIF patients. These two groups were not significantly different in survival after 5 years. From Figure 3, it seems most of the failure occurred early on after index surgery due to migration. After 2 years, survivorship reached plateaus. Average follow-up was 50.1 months.

There were limitations of our study. We had a small sample size. Recall bias could be associated with the telephone follow-up. The patients who had standalone ALIF were older, therefore they have diffuse multi-level facet arthropathy involving non-surgical levels and that certainly could affect their outcome.

To summarize, the clinical outcomes of patients in the ALIF and hybrid groups were similar. The proportions of patients who ranked their surgical result as highly satisfactory and would repeat the surgery were similar in the two groups. With our clinical outcomes in VAS and ODI scores, these results indicate that hybrid fusion is a valid and viable alternative to ALIF fusion, with at least equal if not better clinical outcomes in terms of survivorship, back pain, and disability scores.

Conflicts of interest/disclosures

The authors declare that they have no financial or other conflicts of interest in relation to this research and its publication. Food and Drug Administration (FDA) device/drug status: anterior interbody fusion plates, screws, Charité and ProDisc implants are approved. The hybrid construct is not approved by FDA.

References

- [1] Andersson GB. Epidemiological features of chronic low-back pain. *Lancet* 1999;354:581–5.
- [2] Dmitriev AE, Gill NW, Kuklo TR, et al. Effect of multilevel lumbar disc arthroplasty on the operative- and adjacent-level kinematics and intradiscal pressures: an in vitro human cadaveric assessment. *Spine J* 2008;8: 918–25.
- [3] McAfee PC, Cunningham BW, Hayes V, et al. Biomechanical analysis of rotational motions after disc arthroplasty: implications for patients with adult deformities. *Spine (Phila Pa 1976)* 2006;31:S152–60.
- [4] Schlegel JD, Smith JA, Schleusener RL. Lumbar motion segment pathology adjacent to thoracolumbar, lumbar, and lumbosacral fusions. *Spine (Phila Pa 1976)* 1996;21:970–81.
- [5] Goel VK, Grauer JN, Patel T, et al. Effects of Charite artificial disc on the implanted and adjacent spinal segments mechanics using a hybrid testing protocol. *Spine (Phila Pa 1976)* 2005;30:2755–64.
- [6] Siepe CJ, Mayer HM, Wiechert K, et al. Clinical results of total lumbar disc replacement with ProDisc II: three-year results for different indications. *Spine (Phila Pa 1976)* 2006;31:1923–32.
- [7] Delamarter R, Zigler JE, Balderston RA, et al. Prospective, randomized, multicenter Food and Drug Administration investigational device exemption study of the ProDisc-L total disc replacement compared with circumferential arthrodesis for the treatment of two-level lumbar degenerative disc disease: results at twenty-four months. *J Bone Joint Surg Am* 2011;93: 705–15.
- [8] Erkan S, Rivera Y, Wu C, et al. Biomechanical comparison of a two-level Maverick disc replacement with a hybrid one-level disc replacement and one-level anterior lumbar interbody fusion. *Spine J* 2009;9:830–5.
- [9] Aunoble S, Meyrat R, Al Sawad Y, et al. Hybrid construct for two levels disc disease in lumbar spine. *Eur Spine J* 2010;19:290–6.
- [10] Geisler FH, Blumenthal SL, Guyer RD, et al. Neurological complications of lumbar artificial disc replacement and comparison of clinical results with those related to lumbar arthrodesis in the literature: results of a multicenter, prospective, randomized investigational device exemption study of Charite intervertebral disc. Invited submission from the Joint Section Meeting on

- Disorders of the Spine and Peripheral Nerves, March 2004. *J Neurosurg Spine* 2004;1:143–54.
- [11] Nunley PD, Jawahar A, Mukherjee DP, et al. Comparison of pressure effects on adjacent disk levels after 2-level lumbar constructs: fusion, hybrid, and total disk replacement. *Surg Neurol* 2008;70:247–51 [discussion 251].
- [12] Panjabi M, Malcolmson G, Teng E, et al. Hybrid testing of lumbar CHARITE discs versus fusions. *Spine (Phila Pa 1976)* 2007;32:959–66 [discussion 967].
- [13] Lammi J, Whitaker MC, Moskowitz A, et al. Stand-alone anterior lumbar interbody fusion for degenerative disc disease of the lumbar spine: results with a 2-year follow-up. *Spine (Phila Pa 1976)* 2014;39:E894–901.